

## Navigate here

- » Search
- » Current Issue
- » Submit Article
- » My Preferences

## » Table of Contents - Current issue

**September-October 2017**

Volume 65 | Issue 5





Page Nos. 943-1205

 Online since Wednesday,  
 September 6, 2017

Accessed 371 times.



**PDF access policy**
 Full text access is free in HTML pages; however the journal allows PDF access only to users from **INDIA** and paid subscribers.
**EPub access policy**

Full text in EPub is free except for the current issue. Access to the latest issue is reserved only for the paid subscribers.

-  View issue as eBook
-  Author Institution Mapping
-  Issue statistics
-  RSS




**NI FEATURE - COMMENTARY: THE FIRST IMPRESSION**

- The cover page**  p. 943
-  DOI:10.4103/neuroindia.NI\_724\_17
- [HTML Full text] [PDF] [Mobile Full text] [EPub] [Sword Plugin for Repository]<sup>Beta</sup>


**NI FEATURE - COMMENTARY: TIMELESS REVERBERATIONS**

- Memorable clinical experiences, all in one year at Queen Square, London, United Kingdom (1968-1969): A tribute to Neurology legends**  p. 944
-  K Srinivasan
- DOI:10.4103/neuroindia.NI\_736\_17



[HTML Full text] [PDF] [Mobile Full text] [EPub] [Sword Plugin for Repository]<sup>Beta</sup>

## NI FEATURE: JOURNEY THROUGH THE EONS

- Dr. Harry M. Zimmerman (1901 – 1995): Neuropathologist who autopsied Dr. Harvey Cushing, and his interactions with Indian colleagues**  p. 948

Sunil K Pandya, SK Shankar

DOI:10.4103/neuroindia.NI\_730\_17

[HTML Full text] [PDF] [Mobile Full text] [EPub] [Sword Plugin for Repository]<sup>Beta</sup>

## NI FEATURE: THE EDITORIAL DEBATE I-- PROS AND CONS

- Diffusion tensor imaging in spinal pathology: A robust investigative tool in clinical practice** p. 964

Rishi M Kanna, S Rajasekaran

DOI:10.4103/neuroindia.NI\_735\_17

[HTML Full text] [PDF] [Mobile Full text] [EPub] [Sword Plugin for Repository]<sup>Beta</sup>

- Spinal cord diffusion tensor imaging: Developing a research tool for clinical use** p. 966

Aditya Vedantam

DOI:10.4103/neuroindia.NI\_740\_17

[HTML Full text] [PDF] [Mobile Full text] [EPub] [Sword Plugin for Repository]<sup>Beta</sup>

## NI FEATURE: THE EDITORIAL DEBATE II-- PROS AND CONS

- Muscular dystrophy: The long road ahead**  p. 968

Satish V Khadilkar

DOI:10.4103/neuroindia.NI\_737\_17

[HTML Full text] [PDF] [Mobile Full text] [EPub] [Sword Plugin for Repository]<sup>Beta</sup>

- Muscular dystrophies: An Indian scenario**  p. 969

Atchayaram Nalini, Kiran Polavarapu, Veeramani Preethish-Kumar

DOI:10.4103/neuroindia.NI\_733\_17

[HTML Full text] [PDF] [Mobile Full text] [EPub] [Sword Plugin for Repository]<sup>Beta</sup>

## NI FEATURE: THE EDITORIAL DEBATE III-- PROS AND CONS

- Guillain-Barre syndrome and variants: Antiganglioside** p.

**antibodies** 971

J M K Murthy

DOI:10.4103/neuroindia.NI\_738\_17

[\[HTML Full text\]](#) [\[PDF\]](#) [\[Mobile Full text\]](#) [\[EPub\]](#) [\[Sword Plugin for Repository\]<sup>Beta</sup>](#)**Enigmas in immunobiology of Guillain-Barré syndrome: Ganglioside antibodies and beyond!** p. 973

Madhu Nagappa, Monojit Debnath, Arun B Taly

DOI:10.4103/neuroindia.NI\_728\_17

[\[HTML Full text\]](#) [\[PDF\]](#) [\[Mobile Full text\]](#) [\[EPub\]](#) [\[Sword Plugin for Repository\]<sup>Beta</sup>](#)**Antiganglioside antibody: A hope or hype?** p. 975

Jayantee Kalita, Usha K Misra

DOI:10.4103/neuroindia.NI\_706\_17

[\[HTML Full text\]](#) [\[PDF\]](#) [\[Mobile Full text\]](#) [\[EPub\]](#) [\[Sword Plugin for Repository\]<sup>Beta</sup>](#)**NI FEATURE: THE EDITORIAL DEBATE IV-- PROS AND CONS** **Can arterial spin labelling really replace dynamic susceptibility contrast perfusion techniques for assessing brain tumours in clinical practice?** p. 977

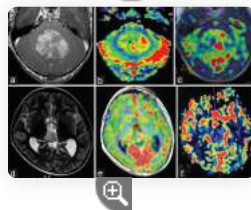
Markand D Patel, Vijay Sawlani

DOI:10.4103/neuroindia.NI\_727\_17

[\[HTML Full text\]](#) [\[PDF\]](#) [\[Mobile Full text\]](#) [\[EPub\]](#) [\[Sword Plugin for Repository\]<sup>Beta</sup>](#)**Arterial spin labelling: A novel promising perfusion technique – Can it be a replacement to dynamic susceptibility contrast MRI ?** p. 979

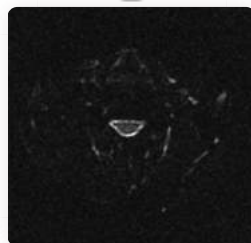
Sona A Pungavkar, Rama Yanamandala

DOI:10.4103/neuroindia.NI\_732\_17

[\[HTML Full text\]](#) [\[PDF\]](#) [\[Mobile Full text\]](#) [\[EPub\]](#) [\[Sword Plugin for Repository\]<sup>Beta</sup>](#)**REVIEW ARTICLES** **The role of diffusion tensor imaging in spinal pathology: A review** p. 982

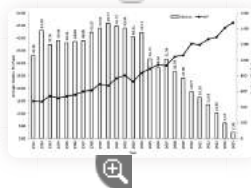
Dan C Li, James G Malcolm, Rima S Rindler, Griffin R Baum, Avinash Rao, Shekar N Khurpad, Faiz U Ahmad

DOI:10.4103/neuroindia.NI\_198\_17

[\[ABSTRACT\]](#) [\[HTML Full text\]](#) [\[PDF\]](#) [\[Mobile Full text\]](#) [\[EPub\]](#) [\[Sword Plugin for Repository\]<sup>Beta</sup>](#)**Global muscular dystrophy research: A 25-year bibliometric perspective** p. 993



Shri Ram

DOI:10.4103/neuroindia.NI\_1241\_16

[\[ABSTRACT\]](#) [\[HTML Full text\]](#) [\[PDF\]](#) [\[Mobile Full text\]](#) [\[EPub\]](#) [\[Sword Plugin for Repository\]<sup>Beta</sup>](#)

## ORIGINAL ARTICLES



- Anti-ganglioside antibodies profile in Guillain-Barré syndrome: Correlation with clinical features, electrophysiological pattern, and outcome** p. 1001
- 
- G Sivaram Naik, A Kanikannan Meena, B Ashok Kumar Reddy, Rukmini K Mridula, Shaik A Jabeen, Rupam Borgohain  
DOI:10.4103/neuroindia.NI\_1226\_15  
[ABSTRACT] [HTML Full text] [PDF] [Mobile Full text] [EPub] [Sword Plugin for Repository]<sup>Beta</sup>
- A study on the clinical outcomes and management of meningitis at a tertiary care centre** p. 1006
- 
- Aparna Yerramilli, Priya Mangapati, Subhashini Prabhakar, Harish Sirimulla, Shravani Vanam, Yashaswini Voora  
DOI:10.4103/neuroindia.NI\_785\_15  
[ABSTRACT] [HTML Full text] [PDF] [Mobile Full text] [EPub] [Sword Plugin for Repository]<sup>Beta</sup>
- Characteristics of nerve conduction studies in carpal tunnel syndrome** p. 1013
- Parag P Moon, Dilip Maheshwari, Vijay Sardana, Bharat Bhushan, Sankalp Mohan  
DOI:10.4103/neuroindia.NI\_628\_16  
[ABSTRACT] [HTML Full text] [PDF] [Mobile Full text] [EPub] [Sword Plugin for Repository]<sup>Beta</sup>

## COMMENTARY



- Carpal tunnel syndrome with equivocal electrophysiological findings: Additional testing may improve diagnostic sensitivity** p. 1017
- Suraj A Muley  
DOI:10.4103/neuroindia.NI\_818\_17  
[HTML Full text] [PDF] [Mobile Full text] [EPub] [Sword Plugin for Repository]<sup>Beta</sup>

## ORIGINAL ARTICLES



- Predictors of quality of life among adolescents with epilepsy in the state of Andhra Pradesh** p. 1019
- M Nagarathnam, B Shalini, V Vijayalakshmi, B Vengamma, S A A Latheef  
DOI:10.4103/neuroindia.NI\_1251\_15  
[ABSTRACT] [HTML Full text] [PDF] [Mobile Full text] [EPub] [Sword Plugin for Repository]<sup>Beta</sup>
- Evaluation of hand function in healthy individuals and patients undergoing uninstrumented central corpectomy for cervical spondylotic myelopathy using nine-hole peg test** p. 1025
- 
- Sanil John, Ranjith K Moorthy, Tunny Sebastian, Vedantam Rajshekhar  
DOI:10.4103/neuroindia.NI\_12\_17  
[ABSTRACT] [HTML Full text] [PDF] [Mobile Full text] [EPub] [Sword Plugin for Repository]<sup>Beta</sup>



**COMMENTARY****Restoration of hand function: A critical parameter during neurorehabilitation, and the confounding factors influencing its evaluation**p.  
1031

K Sridhar, ES Krishnamoorthy

DOI:10.4103/neuroindia.NI\_729\_17

[\[HTML Full text\]](#) [\[PDF\]](#) [\[Mobile Full text\]](#) [\[EPub\]](#) [\[Sword Plugin for Repository\]](#)<sup>Beta</sup>**Nine-hole peg test for evaluation of hand function: The advantages and shortcomings**p.  
1033

Luis Carelli Teixeira da Silva

DOI:10.4103/neuroindia.NI\_739\_17

[\[HTML Full text\]](#) [\[PDF\]](#) [\[Mobile Full text\]](#) [\[EPub\]](#) [\[Sword Plugin for Repository\]](#)<sup>Beta</sup>**ORIGINAL ARTICLE****A novel swine model of subarachnoid hemorrhage-induced cerebral vasospasm**p.  
1035

Zion Zibly, Lory Fein, Mayur Sharma, Yaron Assaf, Anton Wohl, Sagi Harnof

DOI:10.4103/neuroindia.NI\_357\_16

[\[ABSTRACT\]](#) [\[HTML Full text\]](#) [\[PDF\]](#) [\[Mobile Full text\]](#) [\[EPub\]](#) [\[Sword Plugin for Repository\]](#)<sup>Beta</sup>**COMMENTARY****Animal models for cerebral vasospasm: Where do we stand?**p.  
1043

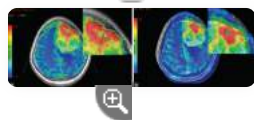
Dhananjaya I Bhat

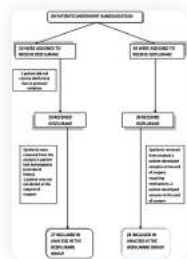DOI:10.4103/neuroindia.NI\_731\_17

[\[HTML Full text\]](#) [\[PDF\]](#) [\[Mobile Full text\]](#) [\[EPub\]](#) [\[Sword Plugin for Repository\]](#)<sup>Beta</sup>**ORIGINAL ARTICLES****Perfusion MR imaging of enhancing brain tumors: Comparison of arterial spin labeling technique with dynamic susceptibility contrast technique**p.  
1046

Neetu Soni, Devender Pal S Dhanota, Sunil Kumar, Awadhesh K Jaiswal, Arun K Srivastava

DOI:10.4103/neuroindia.NI\_871\_16

[\[ABSTRACT\]](#) [\[HTML Full text\]](#) [\[PDF\]](#) [\[Mobile Full text\]](#) [\[EPub\]](#) [\[Sword Plugin for Repository\]](#)<sup>Beta</sup>**A comparison of the recovery profiles of desflurane and isoflurane anesthesia in patients undergoing elective supratentorial craniotomy: A randomized controlled trial**p.  
1053



Aparanjit P Paul, Aditya Vedantam, Grace Korula, Ari G Chacko

DOI:10.4103/neuroindia.NI\_1136\_15

[ABSTRACT] [HTML Full text] [PDF] [Mobile Full text] [EPub] [Sword Plugin for Repository]<sup>Beta</sup>

**COMMENTARY**



**The art of waking up a neurosurgical patient: It is time to hone our skills**

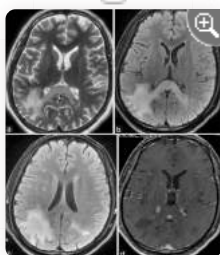
p. 1059

Hemant Bhagat, Ankur Luthra

DOI:10.4103/neuroindia.NI\_674\_17

[HTML Full text] [PDF] [Mobile Full text] [EPub] [Sword Plugin for Repository]<sup>Beta</sup>

**CASE REPORTS**



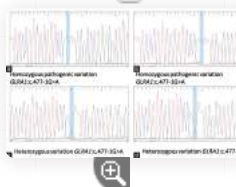**Progressive multifocal leukoencephalopathy in a 44-year old male with idiopathic CD4+ T-lymphocytopenia treated with mirtazapine and mefloquine**

p. 1061

Aruna Nambirajan, Vaishali Suri, Vijay Kataria, Mehar C Sharma, Vinay Goyal

DOI:10.4103/neuroindia.NI\_535\_16

[ABSTRACT] [HTML Full text] [PDF] [Mobile Full text] [EPub] [Sword Plugin for Repository]<sup>Beta</sup>



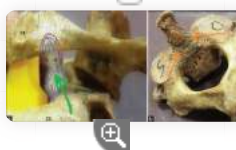
**Hyperekplexia: A forgotten diagnosis clinched by next-generation sequencing**

p. 1065

Meenakshi Lallar, Anukool Srivastava, Shubha R Phadke

DOI:10.4103/neuroindia.NI\_851\_16

[ABSTRACT] [HTML Full text] [PDF] [Mobile Full text] [EPub] [Sword Plugin for Repository]<sup>Beta</sup>



**Simultaneous odontoid excision with bilateral posterior C1-2 distraction and stabilization utilizing bilateral posterolateral corridors and a single posterior midline incision**

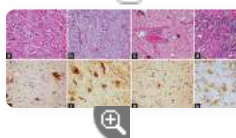
p. 1068

Arun K Srivastava, Sanjay Behari, Jayesh Sardhara, Kuntal Kanti Das

DOI:10.4103/neuroindia.NI\_819\_17

[ABSTRACT] [HTML Full text] [PDF] [Mobile Full text] [EPub] [Sword Plugin for Repository]<sup>Beta</sup>

**NI FEATURE: PATHOLOGY PANORAMA - ORIGINAL ARTICLE**



**BRAF gene alterations and enhanced mammalian target of rapamycin signaling in gangliogliomas**

p. 1076

Aanchal Kakkar, Atraye Majumdar, Pankaj Pathak, Anupam Kumar, Kalpana Kumari, Manjari Tripathi, Mehar C Sharma, Vaishali Suri, Vivek Tandon, Sarat P Chandra, Chitra Sarkar

DOI:10.4103/neuroindia.NI\_207\_17

[ABSTRACT] [HTML Full text] [PDF] [Mobile Full text] [EPub] [Sword Plugin for Repository]<sup>Beta</sup>



**NI FEATURE: THE QUEST - COMMENTARY****Review of tremor in Parkinson's disease and atypical parkinsonian disorders**p.  
1083

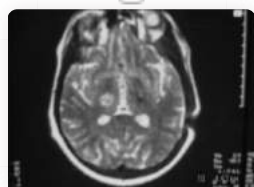
Pooja Mailankody, M Netravathi, Pramod Kumar Pal

DOI:10.4103/neuroindia.NI\_880\_16

[\[ABSTRACT\]](#) [\[HTML Full text\]](#) [\[PDF\]](#) [\[Mobile Full text\]](#) [\[EPub\]](#) [\[Sword Plugin for Repository\]](#)<sup>Beta</sup>**Management strategies in tremors: A bird's eye view**p.  
1091

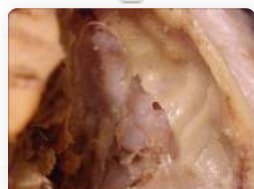Milind Sankhe

DOI:10.4103/neuroindia.NI\_749\_17

[\[HTML Full text\]](#) [\[PDF\]](#) [\[Mobile Full text\]](#) [\[EPub\]](#) [\[Sword Plugin for Repository\]](#)<sup>Beta</sup>**NI FEATURE: CENTS (CONCEPTS, ERGONOMICS, NUANCES, THERBLIGS, SHORTCOMINGS) - COMMENTARY****A neurosurgical perspective to approaches to the orbit: A cadaveric study**p.  
1094

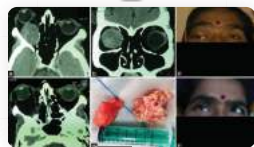S Balaji Pai, MN Nagarjun

DOI:10.4103/neuroindia.NI\_726\_17

[\[ABSTRACT\]](#) [\[HTML Full text\]](#) [\[PDF\]](#) [\[Mobile Full text\]](#) [\[EPub\]](#) [\[Sword Plugin for Repository\]](#)<sup>Beta</sup>**Endonasal endoscopic approach to orbit**p.  
1102

Awadhesh Kumar Jaiswal

DOI:10.4103/neuroindia.NI\_723\_17

[\[HTML Full text\]](#) [\[PDF\]](#) [\[Mobile Full text\]](#) [\[EPub\]](#) [\[Sword Plugin for Repository\]](#)<sup>Beta</sup>**NI FEATURE: CITADELS SCULPTING FUTURE - COMMENTARY****Neurosurgery at Kasturba Medical College: Past, present and future**p.  
1105

Girish Menon, Rajesh Nair, IK Laskhman, Vinod Kumar, G Lakshmi Prasad

DOI:10.4103/neuroindia.NI\_564\_17

[\[ABSTRACT\]](#) [\[HTML Full text\]](#) [\[PDF\]](#) [\[Mobile Full text\]](#) [\[EPub\]](#) [\[Sword Plugin for Repository\]](#)<sup>Beta</sup>**NI FEATURE: THE FOURTH DIMENSION - COMMENTARY****A summary of some of the recently published, seminal papers in neuroscience**p.  
1112

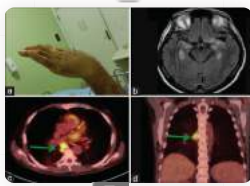
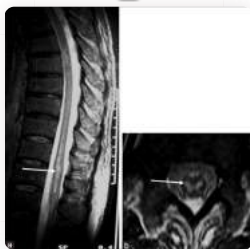
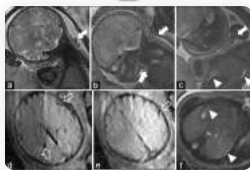

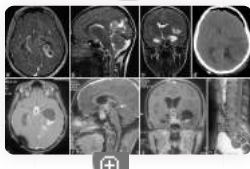
K Sridhar, Mazda K Turel, Manjul Tripathi, Ravi Yadav, PR Srijiithesh, Aastha Takkar, Sahil Mehta, Kuntal K Das, Anant Mehrotra, Chirag K Ahuja

DOI:10.4103/neuroindia.NI\_734\_17

[\[HTML Full text\]](#) [\[PDF\]](#) [\[Mobile Full text\]](#) [\[EPub\]](#) [\[Sword Plugin for Repository\]](#)<sup>Beta</sup>


## NI FEATURE: FACING ADVERSITY...TOMORROW IS ANOTHER DAY! - LETTERS TO EDITOR



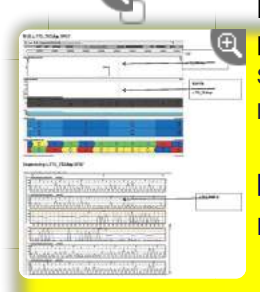
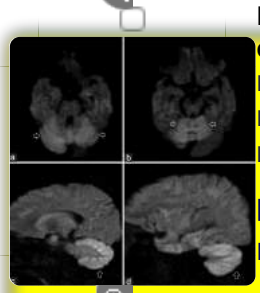
- Multiple paraneoplastic antibodies (anti-SOX1, anti-Hu, and anti-Amphiphysin) detected in a patient with limbic encephalitis and small cell lung cancer** p. 1127  
  
 Thiago Gonçalves Fukuda, Mateus Santana do Rosário, Renan Carvalho Castelo Branco, Jamile Seixas Fukuda, Ricardo Antenor de Souza e Souza, Jamily Oliveira-Filho, Pedro Antonio Pereira de Jesus  
 DOI:10.4103/neuroindia.NI\_1256\_15  
[\[HTML Full text\]](#) [\[PDF\]](#) [\[Mobile Full text\]](#) [\[EPub\]](#) [\[Sword Plugin for Repository\]](#)<sup>Beta</sup>
- Acute spinal cord infarction after aortobifemoral bypass** p. 1128  
  
 Sami Kouki, Emna Labben, Nejmeddine B Abdallah  
 DOI:10.4103/neuroindia.NI\_745\_16  
[\[HTML Full text\]](#) [\[PDF\]](#) [\[Mobile Full text\]](#) [\[EPub\]](#) [\[Sword Plugin for Repository\]](#)<sup>Beta</sup>
- MRI findings in a fetus with a tight cord around the neck** p. 1130  
  
 Haree S Meganathan, R Rajeshwaran, S Bhuvana  
 DOI:10.4103/neuroindia.NI\_671\_16  
[\[HTML Full text\]](#) [\[PDF\]](#) [\[Mobile Full text\]](#) [\[EPub\]](#) [\[Sword Plugin for Repository\]](#)<sup>Beta</sup>
- Neurosarcoidosis-induced longitudinal extensive transverse myelitis** p. 1131  
  
 Sushilkumar S Gupta, Shyam Shankar, Evan Stein, Sina Khasani  
 DOI:10.4103/neuroindia.NI\_505\_16  
[\[HTML Full text\]](#) [\[PDF\]](#) [\[Mobile Full text\]](#) [\[EPub\]](#) [\[Sword Plugin for Repository\]](#)<sup>Beta</sup>
- A case of clear cell ependymoma with bizarre aggressiveness: Are we underestimating its ferocity?** p. 1134  
  
 Kirti Gupta, Manjul Tripathi, Nalini Gupta, Sachin Ranganath, Pravin Salunke  
 DOI:10.4103/neuroindia.NI\_378\_16  
[\[HTML Full text\]](#) [\[PDF\]](#) [\[Mobile Full text\]](#) [\[EPub\]](#) [\[Sword Plugin for Repository\]](#)<sup>Beta</sup>

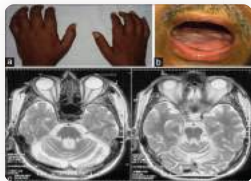

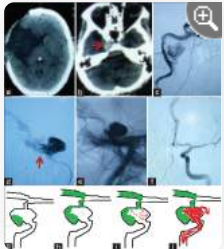

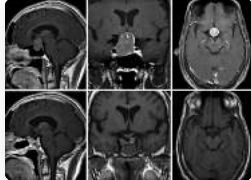
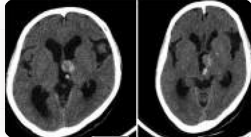
## LETTERS TO EDITOR

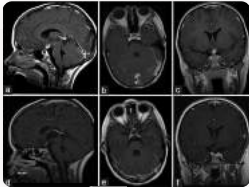



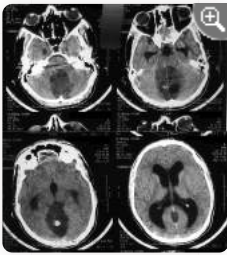
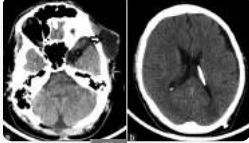



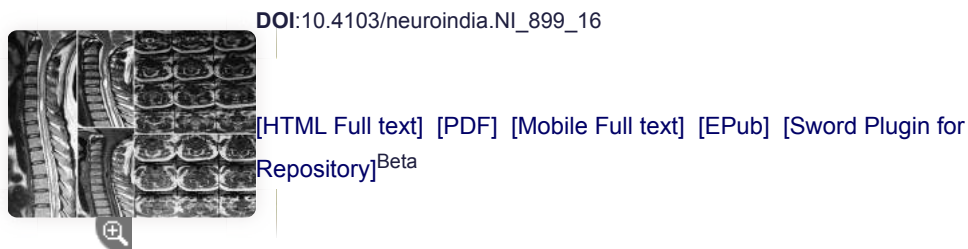
- Acute hemispheritis in children: A report and literature review** p. 1137  
 Riad M Elsayed, Hala E Sayyah  
 DOI:10.4103/neuroindia.NI\_1289\_15  
[\[HTML Full text\]](#) [\[PDF\]](#) [\[Mobile Full text\]](#) [\[EPub\]](#) [\[Sword Plugin for Repository\]](#)<sup>Beta</sup>
- Palatal tremor secondary to a dolichoectatic basilar artery** p. 1138  




|  |   |
|--|---|
|                             | <p>Sanjay Pandey, Arun Koul, Priyanka Tater, Neelav Sarma<br/> <b>DOI:</b>10.4103/neuroindia.NI_983_16<br/> <a href="#">[HTML Full text]</a> <a href="#">[PDF]</a> <a href="#">[Mobile Full text]</a> <a href="#">[EPub]</a> <a href="#">[Sword Plugin for Repository]<sup>Beta</sup></a></p>   |
|                             | <p><b>Novel c.775_781dup,p(Thr261fs) mutation in SPG 7 gene in a patient with hereditary spastic paraparesis</b> p. 1141<br/>           Shakya Bhattacharjee, Victoria Stinton, Diane Cairns, Brian Murray<br/> <b>DOI:</b>10.4103/neuroindia.NI_96_17<br/> <a href="#">[HTML Full text]</a> <a href="#">[PDF]</a> <a href="#">[Mobile Full text]</a> <a href="#">[EPub]</a> <a href="#">[Sword Plugin for Repository]<sup>Beta</sup></a></p>                                     |
| <input type="checkbox"/>   | <p><b>Meningitis, polyradiculopathy, and optic nerve involvement in neurobrucellosis: A rare clinical presentation</b> p. 1142<br/>           Waseem Dar, Muzamil Latief, Imtiyaz Dar, Najeebullah Sofi<br/> <b>DOI:</b>10.4103/neuroindia.NI_127_16<br/> <a href="#">[HTML Full text]</a> <a href="#">[PDF]</a> <a href="#">[Mobile Full text]</a> <a href="#">[EPub]</a> <a href="#">[Sword Plugin for Repository]<sup>Beta</sup></a></p>                                       |
| <input type="checkbox"/>   | <p><b>Anarthria in a patient with bilateral striopallidodentate calcinosis</b> p. 1144<br/>           Shoba Sreenath Meera, N Shivashankar, Ravi Yadav, Maya Dattatraya Bhat<br/> <b>DOI:</b>10.4103/neuroindia.NI_130_17<br/> <a href="#">[HTML Full text]</a> <a href="#">[PDF]</a> <a href="#">[Mobile Full text]</a> <a href="#">[EPub]</a> <a href="#">[Sword Plugin for Repository]<sup>Beta</sup></a></p>  |
| <input type="checkbox"/>  | <p><b>Magnetic resonance imaging findings in heat stroke-related encephalopathy</b> p. 1146<br/>           Ravi K Jakkani, Vijay K Agarwal, Suryanarayana Anasuri, Sriharish Vankayalapati, Rahul Koduri, Sandeep Satyanarayan<br/> <b>DOI:</b>10.4103/neuroindia.NI_740_16<br/> <a href="#">[HTML Full text]</a> <a href="#">[PDF]</a> <a href="#">[Mobile Full text]</a> <a href="#">[EPub]</a> <a href="#">[Sword Plugin for Repository]<sup>Beta</sup></a></p>                |
| <input type="checkbox"/>  | <p><b>Faciobrachial dystonic spells: Presenting feature of autoimmune encephalopathy</b> p. 1149<br/>           Divyanshu Dubey, Abdulradha Alqallaf, Worthy Warnack, Puneet Gupta, Jay Harvey, Steven Vernino<br/> <b>DOI:</b>10.4103/neuroindia.NI_452_16<br/> <a href="#">[HTML Full text]</a> <a href="#">[PDF]</a> <a href="#">[Mobile Full text]</a> <a href="#">[EPub]</a> <a href="#">[Sword Plugin for Repository]<sup>Beta</sup></a></p>                                |
| <input type="checkbox"/>   | <p><b>Stiff-person syndrome after thymectomy in myasthenia gravis mimicking a post-thymectomy myasthenic crisis</b> p. 1152<br/>           Hye Lim Lee, Ju-Hong Min, Jin Myoung Seok, Eun Bin Cho, Sang-soo Lee, Hye Jin Cho, Byoung Joon Kim<br/> <b>DOI:</b>10.4103/neuroindia.NI_493_16<br/> <a href="#">[HTML Full text]</a> <a href="#">[PDF]</a> <a href="#">[Mobile Full text]</a> <a href="#">[EPub]</a> <a href="#">[Sword Plugin for Repository]<sup>Beta</sup></a></p> |
| <input type="checkbox"/>   | <p><b>Spinocerebellar ataxia type 2 associated with amyotrophic lateral sclerosis</b> p. 1153</p>   |

-  Rajesh K Singh, Kamlesh K Sonkar, Sanjeev Bhoi, Jayantee Kalita, Ushakant Misra  
DOI:10.4103/neuroindia.NI\_910\_16  
[\[HTML Full text\]](#) [\[PDF\]](#) [\[Mobile Full text\]](#) [\[EPub\]](#) [\[Sword Plugin for Repository\]](#)<sup>Beta</sup>
- Commentary: Amyotrophic lateral sclerosis: Ongoing search for prognostic biomarkers of longevity**  p. 1155  
Sanjay Pandey, Neelav Sarma  
DOI:10.4103/neuroindia.NI\_7\_17  
[\[HTML Full text\]](#) [\[PDF\]](#) [\[Mobile Full text\]](#) [\[EPub\]](#) [\[Sword Plugin for Repository\]](#)<sup>Beta</sup>
- "Round the Houses" sign and apraxia of eyelid opening in a 62-year old man** p. 1157  
Shakya Bhattacharjee, Kher Lik Ng  
DOI:10.4103/neuroindia.NI\_46\_17  
[\[HTML Full text\]](#) [\[PDF\]](#) [\[Mobile Full text\]](#) [\[EPub\]](#) [\[Sword Plugin for Repository\]](#)<sup>Beta</sup>
- Unusual presentation and temporal events in a patient with cavernous carotid aneurysm** p. 1157  
Swati D Chinchure, Varun Kataria, Om Prakash Lekhara, Rahul Awashi, Ankit Mathur, Rajneesh Kachhara  
DOI:10.4103/neuroindia.NI\_118\_17  
 [\[HTML Full text\]](#) [\[PDF\]](#) [\[Mobile Full text\]](#) [\[EPub\]](#) [\[Sword Plugin for Repository\]](#)<sup>Beta</sup>
- Granular cell tumor at an unusual site masquerading as a neurofibroma** p. 1159  
Irneet Mundi, Ashis Pathak, Ashru K Banerjee, Rahat Brar  
DOI:10.4103/neuroindia.NI\_67\_17  
 [\[HTML Full text\]](#) [\[PDF\]](#) [\[Mobile Full text\]](#) [\[EPub\]](#) [\[Sword Plugin for Repository\]](#)<sup>Beta</sup>
- Thyrotropic pituitary adenoma with plurihormonal immunoreactivity** p. 1162  
Tarang K Vora, Sudish Karunakaran  
DOI:10.4103/neuroindia.NI\_577\_16  
 [\[HTML Full text\]](#) [\[PDF\]](#) [\[Mobile Full text\]](#) [\[EPub\]](#) [\[Sword Plugin for Repository\]](#)<sup>Beta</sup>
- Hemorrhagic colloid cyst** p. 1164  
Girish Menon, Lakshman I Kongwad, Rajesh P Nair, Vinod Kumar  
DOI:10.4103/neuroindia.NI\_909\_16  
 [\[HTML Full text\]](#) [\[PDF\]](#) [\[Mobile Full text\]](#) [\[EPub\]](#) [\[Sword Plugin for Repository\]](#)<sup>Beta</sup>
- Primary pituitary abscess in preadolescence mimicking a sellar mass** p. 1167


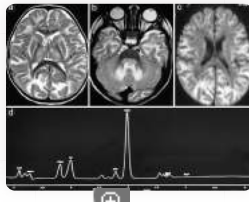
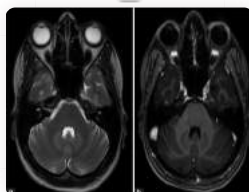
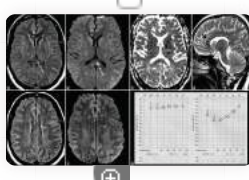
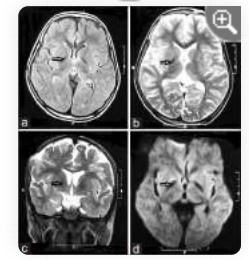
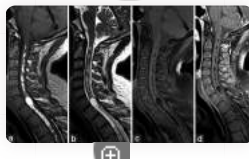
|   |   |         |
|---|---|---------|
|    | Hesam Akbarian-Tefaghi, Kanika Sharma, Piyush Kalakoti, Aileen Cangiano-Heath, Devi Prasad Patra, Papireddy Bollam, Anil Nanda, Bharat Guthikonda<br>DOI:10.4103/neuroindia.NI_997_16<br><a href="#">[HTML Full text]</a> <a href="#">[PDF]</a> <a href="#">[Mobile Full text]</a> <a href="#">[EPub]</a> <a href="#">[Sword Plugin for Repository]</a> <sup>Beta</sup> |         |
| <input type="checkbox"/>  | <b>Intracranial inflammatory pseudotumor presenting as an en plaque mass</b>  | p. 1169 |
|    | Siddharth Gautam, Vengalathur G Ramesh, Kavindapadi V Karthikeyan, Murugan Krishnakumar<br>DOI:10.4103/neuroindia.NI_395_17<br><a href="#">[HTML Full text]</a> <a href="#">[PDF]</a> <a href="#">[Mobile Full text]</a> <a href="#">[EPub]</a> <a href="#">[Sword Plugin for Repository]</a> <sup>Beta</sup>   |         |
| <input type="checkbox"/>  | <b>Management of a case of neglected atlantoaxial rotatory dislocation</b>  | p. 1170 |
|    | Atul Goel, Sonal Jain, Abhidha Shah<br>DOI:10.4103/neuroindia.NI_397_17<br><a href="#">[HTML Full text]</a> <a href="#">[PDF]</a> <a href="#">[Mobile Full text]</a> <a href="#">[EPub]</a> <a href="#">[Sword Plugin for Repository]</a> <sup>Beta</sup>   |         |
| <input type="checkbox"/>  | <b>Dural-based giant cavernous hemangioma mimicking a meningioma: Lessons learnt</b>  | p. 1173 |
|   | Pavan K Pelluru, Alugolu Rajesh, Megha S Uppin<br>DOI:10.4103/neuroindia.NI_1151_15<br><a href="#">[HTML Full text]</a> <a href="#">[PDF]</a> <a href="#">[Mobile Full text]</a> <a href="#">[EPub]</a> <a href="#">[Sword Plugin for Repository]</a> <sup>Beta</sup>   |         |
| <input type="checkbox"/>  | <b>Rosette-forming glioneuronal tumor of the fourth ventricle</b>   | p. 1176 |
|  | Rajashree Pradhan, Sajeeb Mondal, Subrata Pal, Sharmistha Chatterjee, Arindam Banerjee, Debosmita Bhattacharyya<br>DOI:10.4103/neuroindia.NI_862_16<br><a href="#">[HTML Full text]</a> <a href="#">[PDF]</a> <a href="#">[Mobile Full text]</a> <a href="#">[EPub]</a> <a href="#">[Sword Plugin for Repository]</a> <sup>Beta</sup>                                   |         |
| <input type="checkbox"/>  | <b>Subgaleoatrial shunt: Further progress in the management of iatrogenic cranial pseudomeningoceles</b> <span style="background-color: orange; color: white; padding: 2px;">POPULAR</span>   | p. 1178 |
|  | Ananth P Abraham, Edmond Jonathan Gandham, Krishna Prabhu, Ari G Chacko<br>DOI:10.4103/neuroindia.NI_881_16<br><a href="#">[HTML Full text]</a> <a href="#">[PDF]</a> <a href="#">[Mobile Full text]</a> <a href="#">[EPub]</a> <a href="#">[Sword Plugin for Repository]</a> <sup>Beta</sup>   |         |
| <input type="checkbox"/>  | <b>Primary epithelioid hemangioendothelioma of the dorsal spine: A review</b>   | p. 1180 |
|  | Joe M Das, Rony Louis, Sunilkumar BS, Anil Kumar Peethambaran<br>DOI:10.4103/neuroindia.NI_896_16<br><a href="#">[HTML Full text]</a> <a href="#">[PDF]</a> <a href="#">[Mobile Full text]</a> <a href="#">[EPub]</a> <a href="#">[Sword Plugin for Repository]</a> <sup>Beta</sup>   |         |
| <input type="checkbox"/>  | <b>Spontaneous resolution of syringomyelia in Chiari I malformation: A review of literature</b>   | p. 1187 |
|   | Pradeep Kumar Jain, SV Sreeharsha, Suresh Dugani  |         |

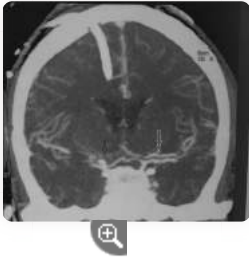





DOI:10.4103/neuroindia.NI\_899\_16

[HTML Full text] [PDF] [Mobile Full text] [EPub] [Sword Plugin for Repository]<sup>Beta</sup>

## NEUROIMAGES

- Gestational Wernicke's encephalopathy** p. 1190  
 Vidhi S Shah, Maheshkumar Shanmugam, Akkayasamy Kowsalya, KG Srinivasan, Prathibha Siddappa, Vellaippan Neethiarasu, Anand K Annamalai  
 DOI:10.4103/neuroindia.NI\_35\_17  
  
 [HTML Full text] [PDF] [Mobile Full text] [EPub] [Sword Plugin for Repository]<sup>Beta</sup>
- Canavan disease with typical brain MRI and MRS findings** p. 1191  
 Anil V Israni, Anirban Mandal  
 DOI:10.4103/neuroindia.NI\_92\_17  
  
 [HTML Full text] [PDF] [Mobile Full text] [EPub] [Sword Plugin for Repository]<sup>Beta</sup>
- Isoniazid toxicity presenting as bilateral dentate hyperintensities** p. 1193  
 Aarthi Deepesh, Hima S Pendharkar  
 DOI:10.4103/neuroindia.NI\_249\_17  
  
 [HTML Full text] [PDF] [Mobile Full text] [EPub] [Sword Plugin for Repository]<sup>Beta</sup>
- A report of third case of Susac syndrome from India** p. 1194  
 Kamble J Harsha, Jeevan S Nair  
 DOI:10.4103/neuroindia.NI\_543\_16  
  
 [HTML Full text] [PDF] [Mobile Full text] [EPub] [Sword Plugin for Repository]<sup>Beta</sup>
- Isolated globus pallidi hypointensities in type 2 GM1 gangliosidosis** p. 1195  
 Mahesh Kamate, Nishant Mittal  
 DOI:10.4103/neuroindia.NI\_926\_16  
  
 [HTML Full text] [PDF] [Mobile Full text] [EPub] [Sword Plugin for Repository]<sup>Beta</sup>
- A rare cause of neck pain: Holocord intramedullary lipoma** p. 1196  
 Sami Kouki, Emna Labben, Nejmeddine B Abdallah  
 DOI:10.4103/neuroindia.NI\_749\_16  
  
 [HTML Full text] [PDF] [Mobile Full text] [EPub] [Sword Plugin for Repository]<sup>Beta</sup>
- Incidental finding of an accessory middle cerebral artery in a patient with multiple aneurysms** p. 1198  
 Manish Garg, Shaam Bodeliwala, Vikas Kumar, Anita Jagetia

|  |   |  |                    |
|--|---|--|--------------------|
|                     | <p>DOI:10.4103/neuroindia.NI_280_17</p>   | <p>[HTML Full text] [PDF] [Mobile Full text] [EPub] [Sword Plugin for Repository]<sup>Beta</sup></p>   |                    |
| <p><b>BOOK REVIEWS</b> <span style="float: right;">↑</span></p>                                      |   |  |                    |
|                     | <p><b>Epilepsy and law in India</b><br/>                 Vikas Dhiman<br/>                 DOI:10.4103/neuroindia.NI_329_17</p> | <p>p.<br/>1201</p>   |                    |
| <p>[HTML Full text] [PDF] [Mobile Full text] [EPub] [Sword Plugin for Repository]<sup>Beta</sup></p> |   | <p><b>Admissions. A life in brain surgery</b><br/>                 Sunil Pandya<br/>                 DOI:10.4103/neuroindia.NI_725_17</p>  | <p>p.<br/>1202</p> |
| <p>[HTML Full text] [PDF] [Mobile Full text] [EPub] [Sword Plugin for Repository]<sup>Beta</sup></p> |    | <p><b>Practical Neurosurgery: Analysis of clinical cases</b> <span style="background-color: orange; color: white; padding: 2px;">POPULAR</span><br/>                 VG Ramesh<br/>                 DOI:10.4103/neuroindia.NI_748_17</p> | <p>p.<br/>1205</p> |
| <p>[HTML Full text] [PDF] [Mobile Full text] [EPub] [Sword Plugin for Repository]<sup>Beta</sup></p> |   |  |                    |

[Site Map](#) | [Home](#) | [Contact Us](#) | [Advertise With Us](#) | [Feedback](#) | [Copyright and Disclaimer](#)

Online since 20<sup>th</sup> March '04

Published by Wolters Kluwer - [Medknow](#)

Editorial and Ethics Policies

 BY-NC-SA
 Open Access
 No Fee
 View mobile site

ISSN: Print -0028-3886, Online - 1998-4022