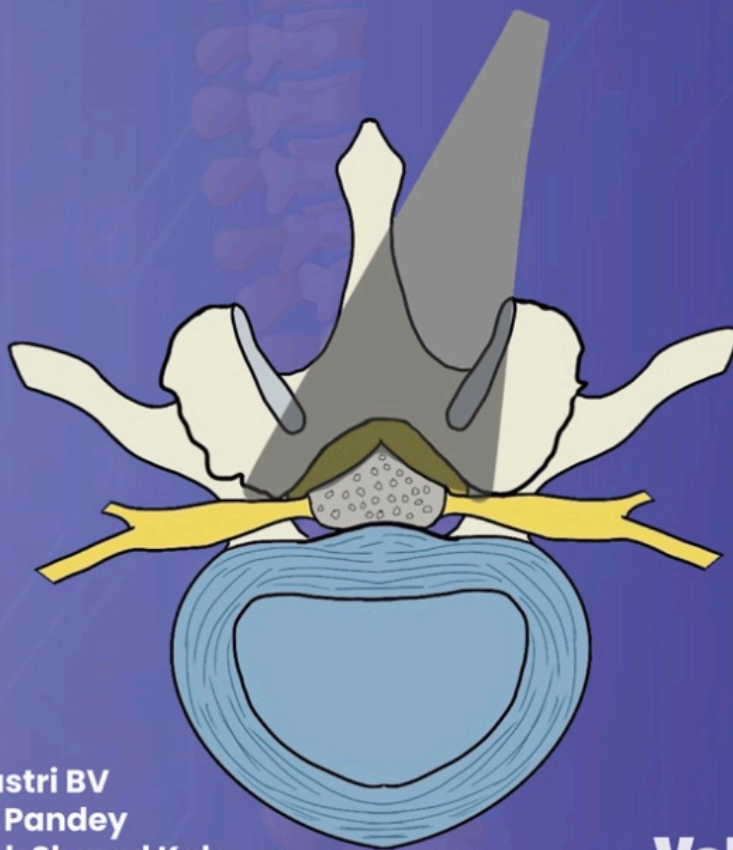


# NEUROSURGERY UPDATES MINIMALLY INVASIVE SPINE SURGERY



Savitr Sastri BV  
Paritosh Pandey  
Shashank Sharad Kale

**Volume 4**



Publication of the  
Neurological Society of India

**BOHR®**  
Publishers



**Publication of the  
Neurological Society of India**

# **NEUROSURGERY UPDATES VOLUME 4 MINIMALLY INVASIVE SPINE SURGERY**

 **BOHR<sup>®</sup>**  
**Publishers**



# NEUROSURGERY UPDATES VOLUME 4

# MINIMALLY INVASIVE

# SPINE SURGERY

---

## *Editors*

**Savitr Sastri BV**  
Senior Consultant Neurosurgeon  
KIMS Hospital, Kondapur,  
Hyderabad, India

**Paritosh Pandey**  
Senior Consultant Neurosurgeon  
Manipal Hospital, Old Airport Road,  
Bangalore, India

**Shashank Sharad Kale**  
Professor and Head,  
Department of Neurosurgery,  
AIIMS, New Delhi, India



# **Neurosurgery Updates Volume 4**

## **Minimally Invasive Spine Surgery**

Editors: Savitr Sastri BV, Paritosh Pandey and  
Shashank Sharad Kale

Published by  
BOHR Publishers, Chennai, India  
Old Door No. 4, New Door No. 3, Rishilaya Building, 2nd Street,  
Golden Avenue, Devi Karumariamman Nagar, Velachery,  
Chennai – 600 042, India

©2023 Neurological Society of India

All rights reserved. No part of this publication may be reproduced or transmitted in any form or by any means, electronic or mechanical, including photocopying, recording or storage in any information or retrieval system, without the prior permission of the copyright owner.

ISBN: 978-93-92892-89-9 (Hardback)

eISBN: 978-93-92892-93-6

Price: Rs. XXXX

Typeset and Cover designed by  
Chennai Publishing Services Pvt. Ltd., Chennai, India

Printed by Ridha Prints Pvt. Ltd., Madurai, India

# Preface

---

Neurosurgery Updates is the distillation of the Super-specialty CMEs conducted by the Neurological Society of India. It gives us great pleasure to put together this volume on Minimally Invasive Spine Surgery. The field of minimally invasive spine surgery has been rapidly gaining popularity both with patients and surgeons due to its benefits in short- and long- term outcomes in spine surgery. This book offers a good starting point for neurosurgeons in training and practice to appreciate the need and concepts of MISS. From the anatomical basis of muscle sparing to the differences in tubular MISS and endoscope assisted and full endoscopic spine surgery, and to recent advances and future prospects, a comprehensive view of current standards and practice of this field has been outlined.

This volume, in addition, also looks at the utility of MISS in various pathologies of the cervical, lumbar and thoracic spine.

We are grateful for this opportunity to bring out this collection and are indebted to the authors who are experts in their field. They are both surgeons and teachers and most importantly passionate in their pursuit of excellence in patient care.

Patient welfare will always be at the core of our profession, and we hope that this book will encourage young neurosurgeons to train and pursue Minimally Invasive Spine Surgery and thus offer their patients cutting edge surgeries with enhanced recovery and long-term relief.

Savitr Sastri BV

Paritosh Pandey

SS Kale



# Foreword

---

The Neurological Society of India, through its Board of Education, has been conducting the Annual Superspecialty CME since 2016. This activity is aimed at exposing the younger neurosurgeons to various subspecialties in neurosurgery. Experts in the field share their experiences and teach surgical nuances to the younger generations. Last year, in 2022, the subject for discussion was Minimally Invasive Spine surgery, and the lectures delivered in the last CME have been compiled in this book, *Neurosurgery Updates*.

Minimally Invasive Spine Surgery is an upcoming and promising specialty in Neurosurgery. The advantages of this, as against the conventional spine surgery, is its smaller scars, less muscle disruption, earlier patient mobilization, and less postoperative pain, among others. The topics for discussion comprised the indications and techniques of tubular and endoscopic spine techniques in lumbar disc disease, decompressions for lumbar canal stenosis, fusions, indications for MIS in dorsal and cervical spine, and advances in MIS techniques.

I congratulate the editors of this volume for compiling the lectures of this CME. I am sure that this book will serve as a valuable addition to libraries of various neurosurgery departments and also a reference guide for all the neurosurgeons.

Prof. Y.R. Yadav  
President  
Neurological Society of India  
Jabalpur

# Foreword

---

The Super- Specialty CME program of the NSI has been a well sought after course that aims to deep dive into a particular subject giving the delegates insight into the various nuances of the same. The subject of the CME in 2022 was a subject that is changing the way Spine Surgery is done – Minimally Invasive Spine Surgery or MISS.

Making the proceedings of the course into an e-book will help take the course to the wider audience of neurosurgeons interested in the subject and wanting to further their knowledge. As Secretary of NSI, it has been my endeavour to see that educational material reaches as many of our members as possible, and that is the reason why we decided to make this an e-book rather than a printed volume.

I would like to congratulate the Editors, Drs Savitr Sastri BV, Paritosh Pandey and SS Kale as well as the Board of Education of the NSI for conducting such a meaningful course and also for taking pains to bring it out as a proper educational volume. The faculty and authors of the chapters have taken pains to put pen to paper their thoughts and ideas on MIS to make it a very good resource for spine surgeons – congratulations and thanks to them for their efforts.

Looking forward to many such successful endeavours by the Board of Education and NSI that would enhance the surgeons' knowledge, patient care and improve patient outcomes.

Krish Sridhar  
November 2023  
Hon Secretary  
Neurological Society of India

# Contributors

---

**Akash Hosthota**

Fellow Spine Surgery, Sakra  
World Hospital, Bangalore, India

**Akshay S Hari**

Consultant Neurosurgeon and  
Spine Surgeon, Aster CMI,  
Bangalore, India

**Alok Ranjan**

Consultant Neurosurgeon, Apollo  
Hospitals, Jubilee Hills,  
Hyderabad, India

**Ashutosh Kumar**

Assistant Professor, Department  
of Neurosurgery, SGPGIMS,  
Lucknow, India

**Baru Dhruvkumar Hiralal**

Fellow Spine Surgery, Sakra  
World Hospital, Bangalore, India

**Chaitanya Prabhu K**

Associate Consultant, Depart-  
ment of Neurosurgery, Fortis  
Hospital, Bangalore, India

**Chandan B Mohanty**

Assistant Professor Neurosurgery,  
Bombay Hospital, Mumbai, India

**Deepak Somasundaram**

Consultant Neurosurgeon and  
Spine Surgeon, Aster CMI,  
Bangalore, India

**Dhiraj K Poonia**

DNB Resident, Department of  
Neurosurgery, Fortis Hospital,  
Bangalore, India

**Hitesh Inder Singh Rai**

Spine Fellow, Department of  
Neurosurgery, AIIMS, New  
Delhi, India

**Jayesh Sardhara**

Senior Consultant Neurosurgeon,  
Fortis Hospital, Mulund, Mumbai,  
India

**Murali Krishna P**

Senior Consultant, Department  
of Neurosurgery, Fortis Hospital,  
Bangalore, India

**Rajakumar V Deshpande**

Director of Neurosurgery, Fortis  
Hospital, Bangalore, India

**Ramachandran Govindasamy**

Associate Consultant, Sakra World  
Hospital, Bangalore, India

**Sachin A Borkar**

Professor, Department of Neuro-  
surgery, AIIMS, New Delhi, India

**Saransh Gupta**

Additional Professor, Department  
of Neurosurgery, AIIMS,  
New Delhi, India

x Contributors

**Satish Rudrappa**

Director of Neurosciences, Sakra  
World Hospital, Bangalore, India

**Savitr Sastri BV**

Consultant Neurosurgeon, KIMS  
Hospital, Kondapur, Hyderabad,  
India

**Soma Madhan Reddy**

Consultant Neurosurgeon, Apollo  
Hospitals, Jubilee Hills,  
Hyderabad, India

**Sukumar Sura**

Chief of Spine Surgery, Asian  
Spine Institute, Hyderabad, India

**Umesh Srikantha**

Senior Consultant Neurosurgeon,  
Head of Spine Services, Aster  
Hospitals, Bangalore, India

**Yadhu K Loknath**

Consultant Neurosurgeon and  
Spine Surgeon, Aster RV,  
Bangalore, India

# Contents

---

<i>Preface</i>	<i>v</i>
<i>Foreword</i>	<i>vii</i>
<i>Contributors</i>	<i>ix</i>
<b>Chapter 1: Introduction to Minimally invasive spine surgery: why, when, how...</b>	<b>1</b>
1. Why MIS?	2
2. Paraspinal muscle injury	3
2.1. Mechanism of paraspinal muscle injury	4
3. When MIS	6
4. How	6
4.1. Microscopic techniques	6
4.2. Endoscopic techniques	7
References	8
<b>Chapter 2: Basic principles of tubular minimally invasive spine surgery</b>	<b>9</b>
1. Tube docking	11
2. Lumbar discectomy	12
3. Spinal decompression	13
4. Transforaminal lumbar interbody fusion	13
5. Decompression and/or discectomy of the cervical spine	14
6. Spinal tumors	14
7. Conclusion	14
References	15
<b>Chapter 3: Spinal Endoscopy-Basics and recent advances</b>	<b>17</b>
1. History, rationale, and nomenclature of spinal endoscopy	17
1.1. Types and classification of endoscopic spinal surgery (ESS)	18
2. Future directions	21
References	22



<b>Chapter 4: MIS–Endoscopy for lumbar disc disease and canal stenosis . . . . .</b>	<b>25</b>
1. Introduction . . . . .	26
2. History . . . . .	26
3. Interlaminar technique . . . . .	27
3.1. Procedure . . . . .	28
4. Spinal stenosis . . . . .	29
5. Current indications . . . . .	30
6. Conclusion and future . . . . .	30
References . . . . .	30
 <b>Chapter 5: Treatment of Lumbar degenerative disc disease and lumbar stenosis- tubular retractor minimally invasive spine surgery . . . . .</b>	<b>31</b>
1. Introduction . . . . .	31
2. Tubular retractor microdiscectomy–Posterolateral disc prolapse .	33
3. Far lateral disc prolapse . . . . .	36
4. Lumbar canal stenosis–Unilateral, over the top decompression .	39
5. Complications of tubular retractor surgery and complication avoidance . . . . .	41
References . . . . .	42
Additional Suggested Reading . . . . .	42
 <b>Chapter 6: Minimally invasive spine surgery for lumbar fusion</b>	<b>43</b>
1. Introduction . . . . .	43
2. Indications . . . . .	44
3. Pre-requisite for MIS . . . . .	45
4. Surgical anatomy . . . . .	45
4.1. Operative setup: positioning and instruments needed. . . . .	46
4.2. Core steps of performing MISS TLIF . . . . .	47
4.2.1. Percutaneous pedicle screw placement . . . . .	47
4.2.2. Docking and landing . . . . .	49
4.2.3. Facetectomy and neural decompression . . . . .	49
4.2.4. End plate preparation and discectomy . . . . .	52
4.2.5. Cage/graft placement . . . . .	53
4.3. Complication and prevention (Table 2) . . . . .	57
4.4. Literature review . . . . .	57
4.5. Special scenarios (Table 3) . . . . .	59
References . . . . .	64

<b>Chapter 7: Percutaneous pedicle screw fixation-Techniques and complication avoidance .....</b>	<b>67</b>
1. Introduction .....	67
2. Indications (1–4) .....	68
3. Rationale of PPSI .....	68
4. Technique of PPSI .....	69
4.1 The surgical steps are as follows (1, 2) .....	69
5. Challenges in PPSI .....	75
5.1. Small, sclerotic pedicles .....	75
5.2. Changing screw trajectory .....	75
5.3. Close proximity of certain screws especially of L5 S1 .....	76
5.4. K wire related .....	76
5.5. Multi-level fixation .....	78
6. Complications and limitations of PPSI .....	78
7. Conclusion .....	79
References .....	79
 <b>Chapter 8: Anterior and lateral minimally invasive approaches to lumbar spine .....</b>	 <b>81</b>
1. Rationale and introduction .....	81
2. Indications .....	84
3. Contra-indications .....	84
4. Technique .....	85
5. OLIF L5-S1 .....	87
6. Clinical outcomes .....	89
7. Summary .....	89
References .....	89
 <b>Chapter 9: Minimally invasive surgery for cervical and thoracic spine .....</b>	 <b>93</b>
1. Introduction .....	94
2. Minimally invasive anterior foraminotomy for cervical radiculopathy .....	194
2.1. Indications .....	95
2.2. Limitations .....	95
2.3. Description of anatomy .....	95
2.4. Surgical technique .....	96
2.5. Postoperative care .....	97
2.6. Complications .....	97
2.6.1. Nerve root injury .....	97
2.6.2. Vertebral artery injury .....	98

## xiv Contents

2.6.3	Horner's syndrome . . . . .	98
2.6.4	Epidural bleeding . . . . .	98
2.6.5	Summary . . . . .	98
3.	Minimally invasive posterior foraminotomy/laminotomy for nerve root decompression . . . . .	99
3.1	Indications . . . . .	99
3.2.	Limitations . . . . .	99
3.3.	Operative technique . . . . .	99
3.4.	Complications . . . . .	100
4.	Conclusion . . . . .	101
5.	Minimally invasive treatment of thoracic disc herniation . . . . .	101
5.1.	Preoperative evaluation . . . . .	101
5.2.	Microendoscopic and microscopic discectomy . . . . .	101
5.3.	Indications: Soft lateral thoracic disc herniation . . . . .	102
5.4.	Transforaminal endoscopic disc removal . . . . .	102
5.4.1.	Indication . . . . .	102
5.4.2.	Technique . . . . .	102
5.4.3.	Complications . . . . .	103
	References . . . . .	103

## **Chapter 10: Advanced applications and future directions . . . 107**

1.	Introduction . . . . .	107
2.	Navigation technologies . . . . .	108
2.2.	Single or biplanar fluoroscopy (non-navigated) . . . . .	109
2.2.	Navigated two-dimensional fluoroscopy . . . . .	109
2.3.	Fan beam and cone beam computed tomography-based three-dimensional navigation . . . . .	110
2.4.	3D "total navigation" . . . . .	110
3.	Advances in optics and visualization technology . . . . .	111
4.	Instruments and implants . . . . .	111
4.1.	Drill . . . . .	111
4.2.	Expandable cages . . . . .	112
4.3.	Energy sources . . . . .	112
4.4.	Expansion of MISS applications with advanced technology	112
4.5.	Future perspective . . . . .	113
5.	Robotics and artificial intelligence . . . . .	113
5.1.	Augmented and virtual reality . . . . .	114
5.2.	Nanotechnology and photonics . . . . .	115
5.3.	Conclusion . . . . .	116
	References . . . . .	116

# Introduction to Minimally invasive spine surgery: why, when, how...

---

**Dhiraj K. Poonia, Murali Krishna P.,  
Chaitanya Prabhu K. and  
Rajakumar V. Deshpande**

Department of Neurosurgery, Fortis Hospitals, Bangalore, India

1. Why MIS? .....	2
2. Paraspinal muscle injury .....	3
2.1. Mechanism of paraspinal muscle injury .....	4
3. When MIS .....	6
4. How .....	6
4.1. Microscopic techniques.....	6
4.2. Endoscopic techniques .....	7
References.....	8

A minimally invasive surgery (MIS) refers to any procedure that is less invasive than open surgery used for the same purpose. The MIS term was first coined by John EA Wickham in 1984 (1). Such a procedure should cause minimal damage to biological tissues at the point of instrument entrance. Minimally invasive spinal procedures and technologies have recently been developed that accomplish the same operative goals as those of open spinal procedures with less disturbance of normal anatomy.

When compared to open cases, the minimally invasive procedure offers improved peri-operative outcomes, improved or equivalent long-term effectiveness, and reduced rate of infection. As opposed

to open spine surgery, minimally invasive surgical approaches can be faster, safer, and require less recovery time. Because of the reduced trauma to the muscles and soft tissues (compared to open procedures), the potential benefits are:

- Better cosmetic results from smaller skin incisions
- Less blood loss from surgery
- Reduced risk of muscle damage
- Reduced risk of infection and post-operative pain
- Faster recovery from surgery and less rehabilitation required
- Diminished reliance on pain medications after surgery

In addition, some MIS surgeries can be performed as outpatient procedures and utilize only local anesthesia—so there is less risk of an adverse reaction to general anesthesia.

## 1. Why MIS?

Goals of MIS surgery include

- (1) decompression in cases where there is symptomatic nerve compression,
- (2) fusion and/or instrumentation in cases when there is instability, and
- (3) realignment in cases when there is clinically relevant deformity.

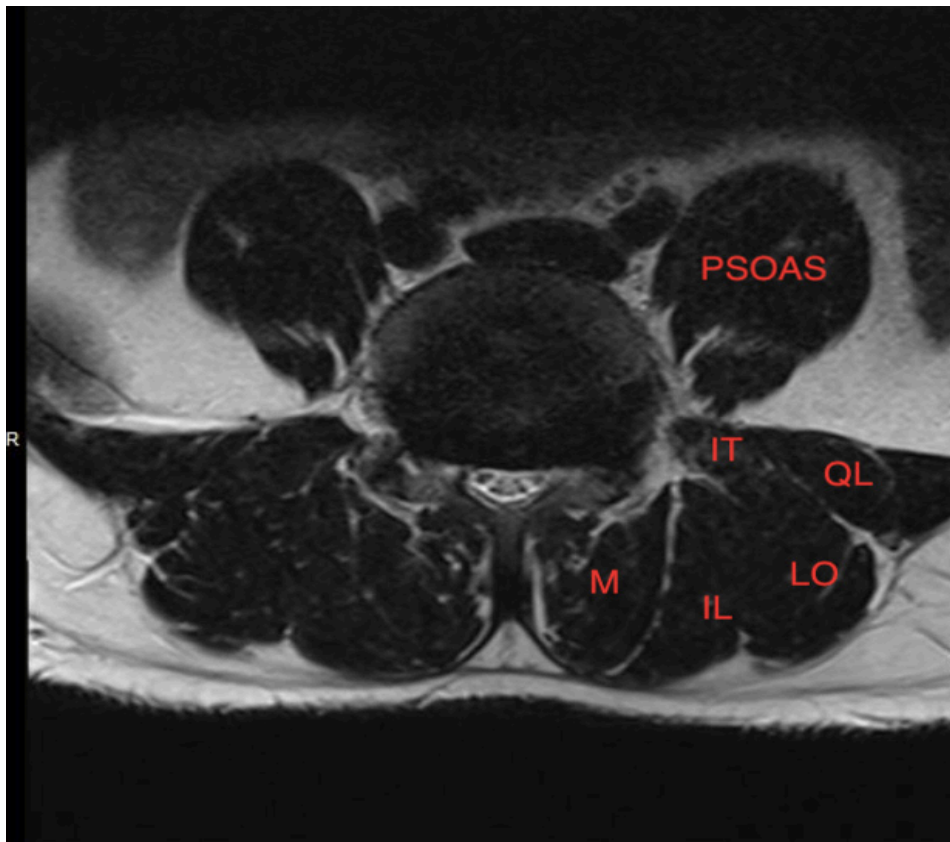
What distinguishes MIS surgery from traditional open surgery is its emphasis on the following:

- (1) avoiding muscle crush injury by self-retaining retractors;
- (2) not disrupting tendon attachment sites of key muscles, particularly the origin of the multifidus muscle at the spinous process;
- (3) using known anatomic neurovascular and muscle compartment planes; and
- (4) minimizing collateral soft tissue injury by limiting the width of the surgical corridor.

The most surgically relevant posterior paraspinal muscles in lumbar region are composed of 3 major muscles:

- (1) multifidus,
- (2) longissimus, and
- (3) iliocostalis.

The multifidus is the most medial of the major posterior paraspinal muscles and is the largest muscle that spans the lumbosacral junction. It is major posterior stabilizing muscle of the spine. It has a large physiologic cross sectional area but short fiber lengths.



**Figure 1** | Muscle group arrangement in lower back-MR cross-sectional image through L4–L5 disc space showing the multifidus (M), iliocostalis (IL), longissimus (LO), quadratus lumborum (QL), intertransversarii (IT), and psoas muscles.

## 2. Paraspinal muscle injury

Spine surgery causes damage to surrounding muscles marked by atrophy and subsequent loss of function. Muscle atrophy coincides with decreased muscle cross sectional area (CSA). Because of its midline location, the multifidus muscle is most severely injured

during a midline approach. Muscle biopsies obtained from patients undergoing revision spinal surgery exhibit pathologic features like

- (a) selective type II fiber atrophy,
- (b) widespread fiber type grouping (a sign of reinnervation), and
- (c) “moth eaten” appearance of muscle fibers (2).

## **2.1. Mechanism of paraspinal muscle injury**

- (1) Direct injury to the muscle is caused by dissection and stripping of tendinous attachments from the posterior elements of the spine. Open, midline laminectomy removes the spinous process. The spinous process is the sole cephalad attachment of the multifidus muscle tendon. Extensive use of the electrocautery causes localized thermal injury and necrosis to the tissues
- (2) Crush Injury: The most significant factor responsible for muscle injury likely because of powerful self-retaining retractors. The injury is caused by a crush mechanism similar to that caused by a pneumatic tourniquet during surgery of the limbs. During the application of self-retaining retractors, elevated pressures lead to decreased intramuscular perfusion. The severity of the muscle injury is correlated with the degree of the intramuscular pressure and the length of retraction time.
- (3) Denervation is another mechanism that leads to muscle degeneration and atrophy after surgery. Muscle denervation can occur in a discrete location along the supplying nerve, or be located in several points along the nerve and the neuromuscular junction. Nerve supply to the multifidus is especially vulnerable to injury because of its monosegmental innervation pattern. Muscle denervation is also possible through damage to the neuromuscular junction following long muscle retraction and necrosis.

Decrease in tissue trauma not only has local effects but also alters overall systemic physiology. Kim et al. (3) studied circulating markers of tissue injury (creatinine kinase, aldolase), pro-inflammatory cytokines (IL-6, IL-8) and anti-inflammatory cytokines (IL-10, IL-1 receptor antagonist) in patients undergoing open versus MIS fusions. There was two to sevenfold increase in all

markers in the open surgery group. The greatest difference between the groups was on the first post-operative day. Most markers returned to baseline in 3 days for the MIS group whereas the open surgery group required 7 days.

Gejo et al. (4) examined the relationship between the time of retraction and post-operative damage to the paraspinal muscle by measuring post-surgery signal intensity of the multifidus muscle, using T2-weighted magnetic resonance imaging (MRI). Long retraction time during surgery was found to correlate with high-signal intensity in the multifidus muscle even at 6 months following surgery. They proposed that these findings reflect chronic denervation of the muscle caused by damage to the neuromuscular synapses.

Sihvonen et al. (5) found signs of severe denervation of the multifidus muscle in patients with failed back syndrome. Muscle biopsies showed signs of advanced chronic denervation consisting of group atrophy, marked fibrosis, and fatty infiltration. They hypothesized that the denervation injury resulted from direct damage to the medial branch of the posterior rami during muscle retraction associated with the posterior midline approach.

Fu et al. (6) observed in 2020 that there was a greater trend of increasing fat infiltration after Open than MIS at the paraspinal muscle.

Kim et al. (7) compared trunk muscle strength between patients treated with open posterior instrumentation versus percutaneous instrumentation. Patients undergoing percutaneous instrumentation displayed more than 50% improvement in extension strength. Patients undergoing traditional midline open surgery had no significant improvement in lumbar extension strength. Extension strength correlated with preservation of multifidus CSA as measured on MRI.

Hyun et al. (8) retrospectively assessed a group of patients that underwent unilateral TLIF with ipsilateral instrumented posterior spinal fusion via an open technique. Contralateral instrumented posterior spinal fusion was performed at the same level using a paramedian, intermuscular (Wiltse) minimally invasive approach. After surgery, there was a significant decrease in the CSA of the multifidus on the side of the open approach, whereas no reduction in the multifidus CSA on the contralateral side was observed.



### **3. When MIS**

The procedures that can be done through MIS technique are

#### **Cervical**

- Cervical lamino-foraminotomy
- Cervical laminoplasty

#### **Dorsal**

- Vertebrectomy
- Thoracoscopic sympathectomy
- Posterior Thoracic Fusion

#### **Lumbar**

- Discectomy
- Decompression
- Lateral foraminotomy
- Interbody fusion (ALIF, PLIF, TLIF, DLIF, OLIF, XLIF)
- Percutaneous pedicle screw fixation
- Vertebroplasty and balloon kyphoplasty
- Deformity correction
- Tumor excision
- Biopsy

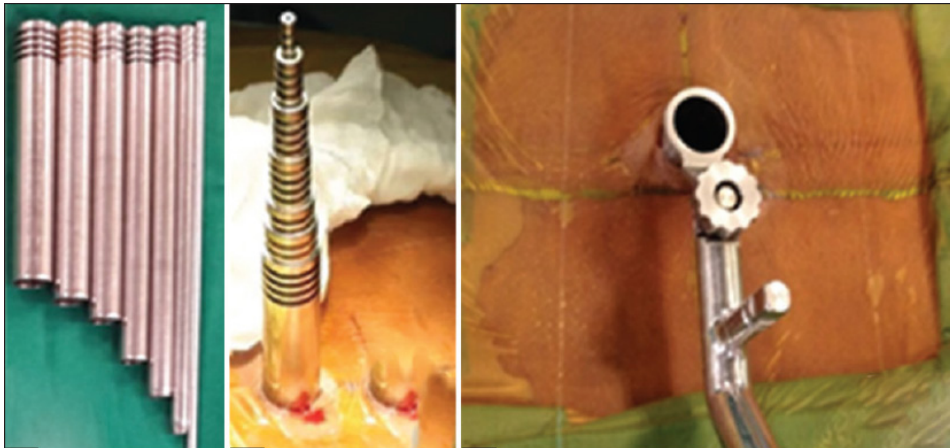
### **4. How**

A number of methods can be used to minimize trauma during MIS surgery.

#### **4.1. Microscopic techniques**

Using a Tubular Retractor

This is a transmuscular approach using a tubular retractor. A “muscle splitting” approach is employed, in which the tubular retractor is passed through a tunnel in the muscles of the back, rather than stripping the muscles away from the spine, as is done in open procedures. This approach limits damage to the muscles around the spine and decreases blood loss during surgery. An operating micro-



**Figure 2** | Minimally invasive surgery tubular retractor.

scope is focused down the tube to assist with performing the surgery through a minimal access strategy. Depending on the extent and type of surgery, incision length can vary.

## **4.2. Endoscopic techniques**

Innovations in endoscopes have led to better illumination, magnification, and 3D depth perception. Also, a greater variety of tools can be inserted through the endoscope, allowing the minimally invasive approach to be an option for more types of surgeries. Spinal fusions as well as decompressions can be performed with an endoscopic approach.

### **A. Full endoscopic procedure**

- Transmuscular approach using endoscope and through “single” incision

### **B. Biportal endoscopic procedure**

- Transmuscular approach using endoscope and through “two” incisions

### **C. Destandau’s technique**

- Endoscopic transmuscular approach using the Endospine system

The scientific basis for MIS surgery relies on a few key concepts.

- Avoiding muscle crush injury by using tubular retractors that minimize retraction pressures in the adjacent soft tissues.
- Focusing the surgical corridor directly over the surgical target site allows for less muscle stripping, which would otherwise disrupt its tendinous attachments or damage their neurovascular supply.
- Using smaller incisions to maintain a narrow surgical corridor that uses known anatomic surgical planes.

## References

1. Wickham A. Introduction. *Br Med Bull.* (1986) 42:221–2.
2. Kim CW. Scientific basis of minimally invasive spine surgery: prevention of multifidus muscle injury during posterior lumbar surgery. *Spine.* (2010) 35:S281–6. doi: 10.1097/BRS.0b013e3182022d32
3. Kim K, Lee S, Suk K, Bae S. The quantitative analysis of tissue injury markers after mini-open lumbar fusion. *Spine.* (2006) 31:712–6.
4. Gejo R, Kawaguchi Y, Kondoh T, Tabuchi E, Matsui H, Torii K, et al. Magnetic resonance imaging and histologic evidence of postoperative back muscle injury in rats. *Spine.* (2000) 25:941–6.
5. Sihvonen T, Hernö A, Paljarvi L, Airaksinen O, Partanen J, Tapaninaho A. Local denervation atrophy of paraspinal muscles in postoperative failed back syndrome. *Spine.* (1993) 18:575–81.
6. Fu C, Chen W, Lu M, Cheng C, Niu C. Comparison of paraspinal muscle degeneration and decompression effect between conventional open and minimal invasive approaches for posterior lumbar spine surgery. *Sci Rep.* (2020) 10:14635. doi: 10.1038/s41598-020-71515-8
7. Kim D, Lee S, Chung S, Lee H. Comparison of multifidus muscle atrophy and trunk extension muscle strength: percutaneous versus open pedicle screw fixation. *Spine.* (2005) 30:123–9.
8. Hyun S, Kim Y, Kim Y, Park S, Nam T, Hong H, et al. Postoperative changes in paraspinal muscle volume: comparison between paramedian interfascial and midline approaches for lumbar fusion. *J Korean Med Sci.* (2007) 22:646–51.

# Basic principles of tubular minimally invasive spine surgery

---

**Alok Ranjan and Soma Madhan Reddy**

Apollo Hospitals, Jubilee Hills, Hyderabad, India

1. Tube docking.....	11
2. Lumbar discectomy .....	12
3. Spinal decompression.....	13
4. Transforaminal lumbar interbody fusion.....	13
5. Decompression and/or discectomy of the cervical spine .....	14
6. Spinal tumors .....	14
7. Conclusion.....	14
References .....	15

Traditionally, spine surgery involves a large incision, dissection, and retraction of the paraspinal muscles of its bony attachments to reach the actual area of interest. The major concerns of open spine surgery are extensive muscle dissection and hemorrhage secondary to it. Nearly three decades ago minimally invasive spine surgery came into existence to address this very issue. Faubert and Caspart were the first to access a lumbar disc using a tubular system in 1991. Since then, with the development of microscopes and endoscopic systems, minimally invasive spine surgery (MISS) has been gaining momentum and has become widely accepted by all spine surgeons across the globe. Tubular access systems have minimized muscle damage and decreased blood loss considerably. Over time with ease of access and overwhelming advantages of its use, the tubular system has become the backbone of minimally invasive spine surgery.

The tubular system has many advantages. It is easily accessible, mechanically less complicated, significantly reduces tissue damage and blood loss, and most importantly, it gives direct visualization of the operative field of interest. It provides a distinct advantage in obese patients where a large cone of exposure is reduced to a small tube. With the addition of an endoscope and microscope, visualization has improved immensely. With rapid developments in optics and illumination of both endoscopes and microscopes, it is only getting better and applications are becoming wider. Micro-endoscopic discectomy was first described by Foley and Smith in 1997 (1). Since then, a plethora of spinal pathologies have been addressed using the tubular system like the depression of spinal canal stenosis, synovial cysts, trauma, degenerative disc disease, spinal instability, and even some spinal tumors. The introduction of a flexible arm has facilitated changing the tube direction, which has helped in contralateral decompression from the ipsilateral approach and multilevel interbody fusions. The MIS tubular system is applied in a wide range of spinal pathologies starting from CV junction to sacrum. Some of the most common applications of MIS tubular systems are lumbar and thoracic discectomies, cervical foraminotomy and discectomy, spinal decompression at cervical to lumbar regions, spinal tumors, and lumbar interbody fusions.

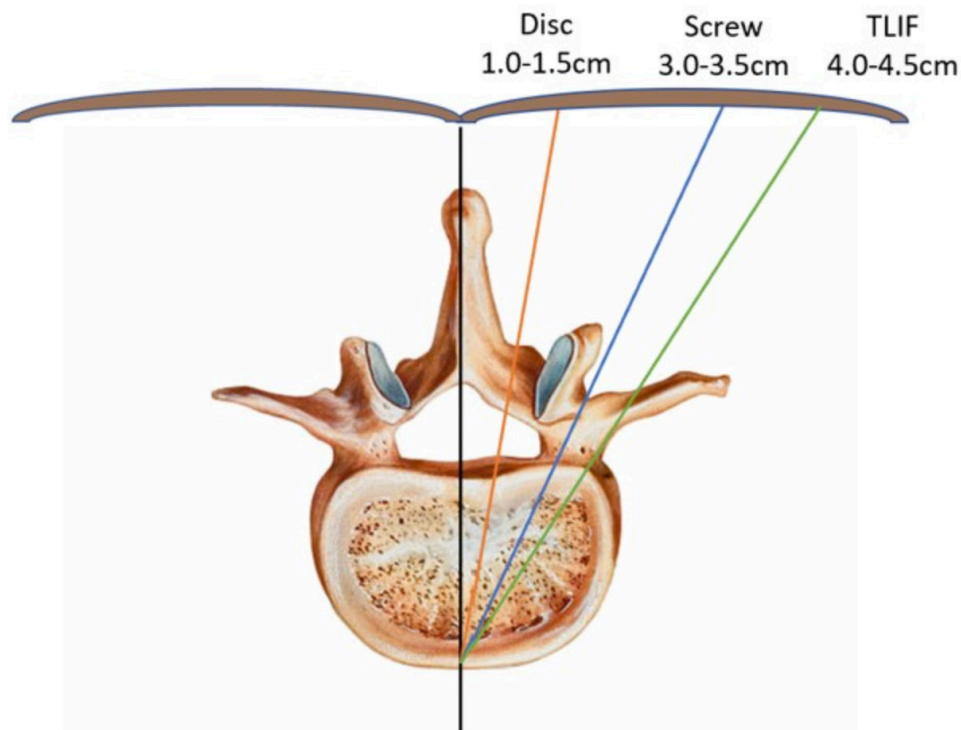
The biggest challenge in using a tubular retractor system is understanding the detailed spinal anatomy, docking of the retractor and instruments used. A good knowledge of these will help to optimize the learning curve and develop a good surgical technique for improved surgical outcomes.

In the early years, polythene tubes and speculums were used for dilatation and access (2, 3). The first commercially available and most widely used tubular system is the METRx system by Medtronic USA. This is a versatile system that enables both endoscopic viewing and direct surgical view under a microscope. It has a wide range of applications stating from the cervical to the lumbar spine. A minor modification of this is the X tube, which allows for tube expansion in the depth using a special dilator. This gives a much wider surgical view at the depth without increasing the skin incision. Tubular retractors are available in a wide range of sizes starting from a diameter of 14 to 26 mm and length from 3 to 9 cm. A flexible arm is used to secure the tube in place. The advantage of this

arm is that it allows for a wide range of tubular movement and hence the viewing angle. All the instruments used are specially designed with minor variations in length and angle for an unobstructed view. They are coated with black paint to avoid light reflection. The initial common step of tube docking is described below followed by a brief description of some of the most common procedures done using the tubular retractor system.

## 1. Tube docking

This is the first step in any surgery using tubular retractors. Since the view is limited, an ideal docking becomes extremely crucial for optimal surgery. A good understanding of the spinal anatomy and pathology from preoperative imaging is key to this. The skin entry varies for each procedure. As depicted in Figure 1, for a discectomy the skin entry is ideally placed at 1 to 1.5 cm from the midline and the distance from the midline increases to 4.0–4.5 cm for a TLIF.



**Figure 1** | Skin entry points for various procedures using tubular retractor system.

In the case of a paracentral disc prolapse, the center of the tube is targeted at the junction of the spinous process and lamina in the axial view and the edge of the lamina in the sagittal view. The direction of the tube in the sagittal view should be aimed in line with the disc space. Little lateral orientation in AP view may result in excessive removal of the facet compromising the spinal stability. However, minor modifications to this can be made based on the location of the extruded or migrated disc to get it in line with the center of the tube.

The procedure starts with the insertion of a 20 G spinal needle under fluoroscopy in lateral view from the skin entry point as described above. The skin is infiltrated with diluted 0.5% sensorcaine. Following a skin incision measuring approximately 1.0 cm and parallel to the midline, a small opening is made in the fascia to facilitate the easy introduction of dilators. Initial entry is made with the blunt end of a K-wire. Care should be taken not to puncture the dura while introducing the K-wire. Once the K-wire is secure in the desired position in both AP and lateral views, serial dilators are introduced confirming the target site and finally the working tube is docked and secured with a flexible arm. A final confirmation X-ray is taken and from there next steps depend on each procedure as described below.

## **2. Lumbar discectomy**

This was the first and still is the most common procedure done using the tubular system. A tube diameter of 20 mm is commonly used and the length depends on the patient's physique. Using a very large tube can damage muscles and is usually not required as the size of laminotomy needed for a discectomy is approximately 15 to 20 mm. After docking the tube, most often the view is still obstructed by a few muscle fibers that are pushed inward from the edge of the tube. This can be minimized by readjusting the tube under vision. Cauterizing the muscles may result in the risk of postoperative pain hence care should be taken to avoid excessive cauterization of muscles. After exposing the lamina, laminotomy is performed using a high-speed drill and punch. Flavectomy is then completed and the disc is exposed by retraction of the nerve root. Discectomy is performed similarly to conventional surgery. The tube is then removed and the skin is closed in layers.



### **3. Spinal decompression**

Minimally invasive spine surgery using the tubular system is an excellent indication for decompression of spinal stenosis. Bilateral or unilateral decompression as indicated can be accessed by tilting the tube attached to the flexible arm. Using a high-speed drill and punches of various sizes, laminotomy and flavectomy can be done to achieve a good spinal canal and bilateral lateral recess stenosis. Special care must be taken to avoid dural tears as chronically compressed dura tends to be thin and very vulnerable to tears. Good control of bleeding is crucial as large dilated veins tend to bleed easily flooding the surgical site. Even a minor hematoma can cause significant post-operative radicular pain and may need reexploration. The placement of drains is usually not indicated.

### **4. Transforaminal lumbar interbody fusion**

Transforaminal lumbar interbody fusion from the posterior approach was popularized by Harms (4, 5). The advantage of this paramedian approach is that the contralateral structure is preserved and there is minimal dural and root retraction compared to a posterior lumbar interbody fusion. However, conventional TLIF involves extensive muscle dissection and damage, which can cause severe post-op pain and long-term problems that can negate the beneficial effects of fusion surgery. A minimally invasive spine technique is an excellent solution to this problem. Schwender et al. first reported his series of minimally invasive TLIF using a tubular retractor system (6). There has been significant improvement both in instrumentation and in technique since then. MIS TLIF is concluded to be a safe procedure by Issac et al. (7). They have reported significantly decreased intraoperative blood loss, less muscle damage, a postoperative pain in their series. A standard MIS TLIF procedure involves a skin entry at 4 to 4.5 cm from mid-line for a lateral entry. A large-diameter tube is needed. Alternatively, X-tube or quadrant retractor system enables a convenient wider operating field. After docking the tube, laminectomy and facetectomy are performed using a high-speed drill, punches, and chisel. Discectomy is then completed, and endplate preparation is performed. Autologous bone graft in the space will enhance bony fusion. A TLIF cage is impacted into the disc space to complete the fusion procedure. Interbody fixation is then done with percutaneous pedicle screws and rods.



## **5. Decompression and/or discectomy of the cervical spine**

Since the introduction of a tubular system for spine surgeries, several surgeons have performed cervical discectomies and foraminotomy using this system (1, 8, 9). Posterior cervical foraminotomy was described in detail by Hilton following his extensive surgical series involving 222 cases (10, 11). Posterior cervical foraminotomy and discectomy is the most common surgery performed using the tubular system in the cervical spine. The approach is similar to the lumbar spine except that the docking of the tube is less angled and mostly directed vertical pointing to the facet lamina junction. Part of the facet is drilled using a high-speed drill and a flavectomy is done to decompress the root. A herniated disc can be retrieved either from the axilla or from the shoulder of the exiting root. Care should be exercised to avoid excessive pressure of retraction on the cord. Spinal decompression for stenosis is similar to lumbar decompression. Damage to facet joints should be avoided in these cases.

## **6. Spinal tumors**

Recent advances in minimal access spine surgery have enabled the expansion of the scope of procedures that can be performed using tubular systems. Spinal intradural extramedullary tumors which were traditionally done by open surgery techniques, can now be performed using the tubular system. The procedure is similar to spinal decompression. Following laminotomy, flavectomy and adequate exposure of dura, durotomy is done and the tumor is excised completely. Dural closure is done to complete the procedure. However, a long intradural tumor spanning multiple levels cannot be performed using this technique.

## **7. Conclusion**

The tubular system is a safe and effective minimal-access technique. It is rapidly evolving with various spinal surgeries being performed effectively using this minimal-access technique. A precise anatomical knowledge and careful application of the technique are mandatory to achieve optimal outcomes. It has significantly reduced postoperative

morbidity and enabled early mobilization. Further advancements in instrumentation and techniques are needed to effectively treat more complex and extensive lesions using a tubular system.

## References

1. Foley K, Smith M. Microendoscopic discectomy. *Tech Neurosurg.* (1997) 3:301–7.
2. Hashizume H, Kawakami M, Kawai M, Tamaki T. A clinical case of endoscopically assisted anterior screw fixation for the type II odontoid fracture. *Spine.* (2003) 28:E102–5.
3. Obenchain T. Speculum lumbar extraforaminal microdiscectomy. *Spine J.* (2001) 1:415–20.
4. Hams J, Jeszebszky D. The unilateral transforaminal approach for posterior lumbar interbody fusion. *Orthop Traumatol.* (1998) 6:88–99.
5. Hams J, Rollinger H. A one-stage procedure in operative treatment of spondylolisthesis: dorsal traction-reposition and anterior fusion. *Z Orthop IHRE Grenzgeb.* (1982) 120:343–437.
6. Johnson M, Tomes D, Treves J, Leibrock L. Minimally invasive implantation of epidural spinal cord neurostimulator electrodes by using a tubular retractor system: technical note. *J Neurosurg.* (2004) 100:1119–21.
7. Issacs R, Podichetty V, Santiago P, Sandhu F, Spears J, Kelly K, et al. Minimally invasive microendocopy-assisted transforaminal lumbar interbody fusion with instrumentation. *J Neurosurg Spine.* (2005) 3:98–105.
8. Adamson T. Microendoscopic posterior cervical laminoforaminotomy for unilateral radiculopathy: results of a new technique in 100 cases. *J Neurosurg Spine.* (2001) 95(Suppl. 1):51–7.
9. Tomaras C, Blacklock C, Parker W, Harper R. Outpatient surgical treatment of cervical radiculopathy. *J Neurosurg.* (1997) 87:41–3.
10. Hilton D. Minimally invasive tubular access for posterior cervical foraminotomy with three-dimensional microscopic visualization and localization with anterior/posterior imaging. *Spine J.* (2007) 7:154–8.
11. Hilton D Jr, Vardiman A. Posterior cervical foraminotomy with three-dimensional visualization with minimally invasive tubular retractor (MITR). *Proceedings of the Oral presentation, AANS/CNS Section on Disorders of the Spine and Peripheral Nerves, 19th Annual Meeting Proceedings.* Tampa, FL (2003).



# Spinal Endoscopy-Basics and recent advances

---

**Chandan B. Mohanty and Savitr Sastri BV**

Bai Jerbai Wadia Hospital for Children,  
Bombay Hospital Institute of Medical Sciences, Mumbai, India  
Neurosurgeon and Minimally Invasive Spine Surgeon,  
KIMS Hospital, Kondapur, Hyderabad, Telangana, India

1. History, rationale, and nomenclature of spinal endoscopy.....	17
1.1. Types and classification of endoscopic spinal surgery (ESS).....	18
2. Future directions.....	21
References .....	22

## 1. History, rationale, and nomenclature of spinal endoscopy

Burman first described spinal endoscopy 1931 as “myeloscopy” where it was mainly used as a visualization tool (1). This situation remained the same until the refinement of optical systems. Interestingly, spinal endoscopy as a tool was widely pursued only in the 1990 and early 2000. Kambin first described the “Kambin’s triangle,” a posterolateral corridor to the disc space (2). Interestingly, he described the spinal endoscopy in this paper as “spinal arthroscopy.” Thus, a new safe “transforaminal” route to the lumbar disc space was now available. This was quickly followed by a large series of 110 patients who underwent an endoscopic transforaminal procedure (3). The “interlaminar” spinal endoscopy was first described by Foley et al. with his tubular system in 1997 and thus the endoscope became an important visualization tool for performing safe minimally invasive spinal procedures (4). Foley described his technique

as “microendoscopy” (4). Despite the early enthusiasm to integrate the endoscope with the tubular spinal systems, some surgeons realized that integration of the microscope with the tubular system was better since the endoscopy optical system was still in a nascent stage of development. However, the name “microendoscopy” still persisted as proposed by Foley though the endoscope was abandoned in favor of a microscope. Thus, the correct nomenclature of tubular systems

**Table 1** | Comparison of endoscopy and tubular microscopy in spine surgery.

Endoscopy	Tubular microscopy
The lens is located closer to the operative field – better image, better illumination	Better color resolution
Corners of the operative field seen better (30-degree endoscope)	3D depth perception possible
No vision impedance or “shadow” due to the visualized tube	Theoretically more working channel
Constant focus-depth adjustment is not required	No fogging of the lens
Hands and instruments do not block the view	
Better surgeon ergonomics and comfort	
Excellent teaching tool	

used with a microscope should be “tubular microscopy.” This distinction becomes important as we will see in the later sections of this paper. We describe the rationale and compare the advantages and disadvantages of endoscopic spine surgery with those of microscopical spine surgery (Table 1).

### 1.1. Types and classification of endoscopic spinal surgery (ESS)

The three ways to classify the spinal endoscopy system are as follows:

- (1) By route—anterior, posterior, interlaminar, transforaminal, caudal.
- (2) By Size and number of ports—uniportal (full endoscopy), biportal, and tubular endoscopy (microendoscopy).
- (3) By visualization medium—air, fluid.

**Table 2** | Differences between interlaminar and transforaminal spinal endoscopy.

<b>Interlaminar</b>	<b>Transforaminal</b>
Approach through a familiar trajectory and anatomy (posterior approach)	Approach is through the Kambin triangle, (posterolateral approach)
Can access all cervical and lumbar levels	L5-S1 is difficult (requires trans-iliac approach)
Can be done under local anesthesia	Usually done under local anesthesia
Minimal paraspinal muscle injury	No paraspinal muscle injury
The incision is usually 0.5 to 1 cm from the midline	Point of entry requires meticulous planning based on level, habitus, and location of disc herniation
Can be performed easily in migrated discs and degenerative scoliosis	Difficult in the significantly migrated disc (may require modification)
Lesser fluoroscopy time	More fluoroscopy time
A higher incidence of dural tears reported	–
Visualization of the thecal sac and neural elements is first	Reaches disc first

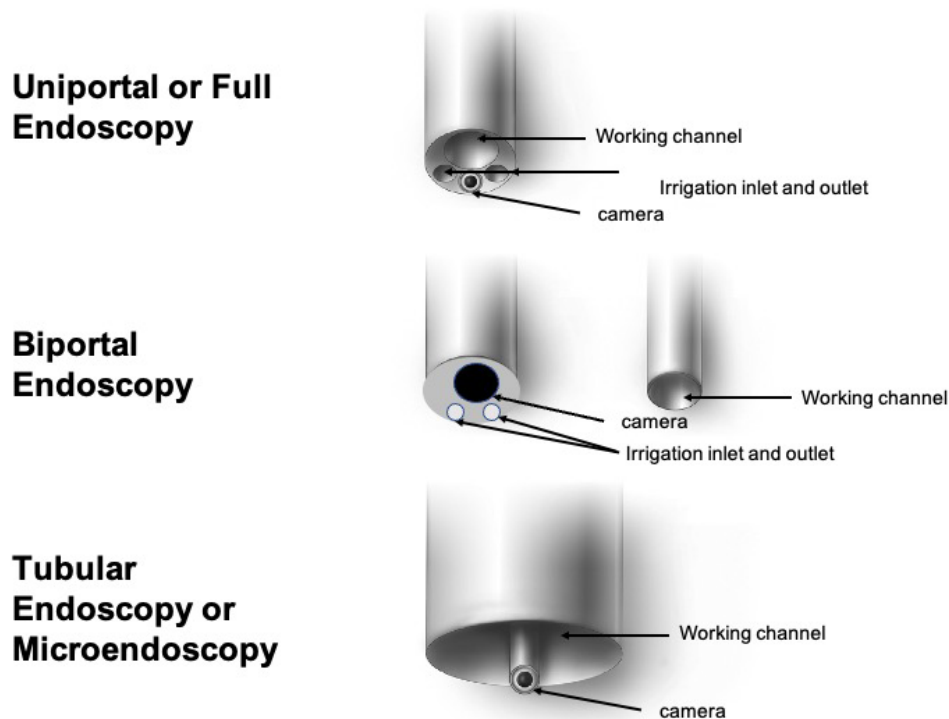
The most commonly employed approaches to the lumbar spine are the interlaminar and transforaminal approaches. The differences between interlaminar and the transforaminal approaches are described in Table 2. Interlaminar approaches are generally more versatile and can tackle the entire spectrum of spinal degenerative diseases which are amenable by conventional posterior approaches in sharp contrast to transforaminal approaches, which have somewhat narrow indications.

Full endoscopy or uniportal endoscopy or percutaneous endoscopy generally utilizes the fluid medium to create additional working space in the surgical field (5). This also helps in keeping the surgical field clean and helps in local hemostasis as well. The working channel of the uniportal system typically allows the use of only one instrument at a time. The main advantage of this system is that it uses the smallest size of the port compared to other systems and hence has the least amount of collateral damage.

Similar to the uniportal system, the biportal system also utilizes the aqueous medium for visualization with the same advantages.

The biportal system, as the name suggests, consists of two working channels, one for the endoscopic visualization and the other for the instruments. This technique thus has principles somewhat similar to those of arthroscopy techniques and may be preferable for surgeons with arthroscopic experience (5).

Tubular endoscopy essentially involves a single larger working channel which allows the simultaneous use of an endoscope with two instruments (5). In contrast with other endoscope systems, this working channel is large enough to accommodate placement of the implants. However, a larger size of the port theoretically also leads



**Figure 1** | Comparison of the working channels of the three commonly used spinal endoscopy systems [adapted from Simpson et al. (5)].

to more collateral damage. Tubular endoscopy is typically performed in the conventional air medium or dry field. This technique is also called as microendoscopy as proposed by Foley et al. However, given the non-usage of the microscope in this technique, the term tubular endoscopy may be preferred (4).

The different working channels of these three commonly used spinal endoscopy systems are depicted in Figure 1 (5).

## Indications and current evidence

A rapid rise in publications regarding endoscopic spine surgery has been noted since 2016 (5). The common indications of spinal endoscopy are as follows (5).

- (1) Lumbar disc herniation  
This is the most common indication for ESS. There have been several randomized controlled trials comparing ESS, minimally invasive, and open techniques. Though older RCTs did show some advantages in terms of outcomes, the newer RCTs failed to show an advantage of ESS (6, 7). Results of transforaminal and interlaminar endoscopic surgery have shown better ODI improvement in the interlaminar group with an equivalent pain score (5, 8).
- (2) Lumbar spinal stenosis  
Endoscopic studies have results generally equivalent to those of other minimally invasive or open techniques with some papers also showing benefit in total hospital stay and reduced operative time (5, 9).
- (3) Lumbar spondylolisthesis  
Purely endoscopic decompression without fusion in patients with lumbar stenosis and listhesis has shown long-term results equivalent to those in patients with only spinal stenosis without listhesis (10).
- (4) Lumbar facet cyst  
Endoscopic management of lumbar facet cysts shows good symptomatic relief in more than 82% cases (5).
- (5) Posterior cervical endoscopic discectomy and foraminotomy (PCDEF)  
Level 1 RCT has shown PCDEF has shown results equivalent to those of anterior cervical discectomy and fusion (6). Thus, PCDEF is an excellent motion-preserving procedure for patients with cervical radiculopathy.

## 2. Future directions

Spinal endoscopy is one of the most rapidly advancing branches of neurosurgery and minimal access spine surgery. Often termed ultra-minimally invasive surgery, the initial trans-Kambin lumbar dis-



cectomy is now established as the treatment for lumbar disc disease. Furthermore, with the development of interlaminar approaches for lumbar degenerative disease and the development of “stemoscope” (RIWOspine), unilateral approaches to bilateral decompression in lumbar canal stenosis are also now routinely done.

Endofusion has been described initially for degenerative lumbar disc disease with collapsed disc and pain, or unilateral stenosis (11, 12). Select patients with low-grade spondylolisthesis are candidates for this procedure. With continuous development of newer instruments, cages designed for endoscopic deployment, and nanomaterials for bone grafting, endofusion will become a fairly common surgery, on a par with the current minimally invasive TLIF standard.

Navigation in Spinal Endoscopy has recently been introduced. In conventional transforaminal approaches, the initial incision is planned on a preoperative MRI and entry into Kambin’s triangle is confirmed with fluoroscopy. This step of the procedure is one that has a learning curve and surgeons only get better with experience. Introduction of intraoperative imaging and navigation reduces the error in the positioning of the endoscope and allows for exact targeting based on the site of pathology. (13).

Camera technology and image projection systems have come a long way from the time that a 3-chip endoscopy camera was considered top of the line. Current endoscopy systems use 4K cameras and high-resolution monitors and give excellent tissue details. 3D endoscopy cameras are commonly used now in laparoscopic and intracranial endoscopy but have not yet been extensively used in spine surgery.

Augmented Reality, Virtual Reality, and Robotics are the three newest technologies that have made an impact in surgery. Augmented reality has been used to assist in pedicle screw placement though its utilization in endoscopic spine is limited to research and few preclinical trials. Virtual reality remains an indispensable tool in training and has formed part of the training of future endoscopic spine surgeons in some centers (14). Robotics in spine surgery has been used to ensure precise placement of percutaneous pedicle screws and since the available platforms are navigation based, their utility currently would lie in providing the ideal access for the endoscope based on pre- and intraoperative determination of the correct depth and angle. With rapid progress in artificial intelligence and machine learning, the near future may see little human intervention in the planning of these surgeries.

The challenge in endoscopic spine surgery remains access and the cost of the equipment. With more spine surgeons recognizing the utility of this subspecialty, this will soon change.

## References

1. Burman M. Myelography or the direct visualization of the spinal canal and its contents. *JBJS*. (1931) 13:695–6.
2. Kambin P. Diagnostic and therapeutic spinal arthroscopy. *Neurosurg Clin N Am*. (1996) 7:65–76.
3. Ditsworth D. Endoscopic transforaminal lumbar discectomy and reconfiguration: a postero-lateral approach into the spinal canal. *Surg Neurol*. (1998) 49:588.
4. Foley K. Microendoscopic discectomy. *Tech Neurosurg*. (1997) 3:301–7.
5. Simpson A, Lightsey H IV, Xiong G, Crawford A, Minamide A, Schoenfeld A. Spinal endoscopy: evidence, techniques, global trends, and future projections. *Spine J*. (2022) 22:64–74.
6. Ruetten S, Komp M, Merk H, Godolias G. Full-endoscopic cervical posterior foraminotomy for the operation of lateral disc herniations using 5.9-mm endoscopes: a prospective, randomized, controlled study. *Spine*. (2008) 33:940–8.
7. Teli M, Lovi A, Brayda-Bruno M, Zagra A, Corriero A, Giudici F, et al. Higher risk of dural tears and recurrent herniation with lumbar micro-endoscopic discectomy. *Eur Spine J*. (2010) 19:443–50.
8. Yu P, Qiang H, Zhou J, Huang P. Percutaneous transforaminal endoscopic discectomy versus micro-endoscopic discectomy for lumbar disc herniation: two-year results of a randomized controlled trial. *Spine*. (2020) 45:493–503.
9. McGrath L, White-Dzuro G, Hofstetter C. Comparison of clinical outcomes following minimally invasive or lumbar endoscopic unilateral laminotomy for bilateral decompression. *J Neurosurg Spine*. (2019) doi: 10.3171/2018.9.SPINE18689 [Epub ahead of print].
10. Youn M, Shin J, Goh T, Son S, Lee J. Endoscopic posterior decompression under local anesthesia for degenerative lumbar spinal stenosis. *J Neurosurg Spine*. (2018) 29:661–6.
11. Brusko G, Wang M. Endoscopic lumbar interbody fusion. *Neurosurg Clin N Am*. (2020) 31:17–24.
12. Kim HS, Wu PH, Sairyo K, Jang I. A narrative review of uniportal endoscopic lumbar interbody fusion: comparison of uniportal facet-preserving trans-Kambin endoscopic fusion and uniportal facet-sacrificing posterolateral transforaminal lumbar interbody fusion. *Int J Spine Surg*. (2021) 15(Suppl 3):S72–83.
13. Hagan M, Remacle T, Leary O, Feler J, Shaaya E, Ali R, et al. Navigation techniques in endoscopic spine surgery. *Biomed Res Int*. (2022) 2022:8419739. doi: 10.1155/2022/8419739
14. Lohre R, Wang J, Lewandrowski K, Goel D. Virtual reality in spinal endoscopy: a paradigm shift in education to support spine surgeons. *J Spine Surg*. (2020) 6(Suppl 1):S208–23. doi: 10.21037/jss.2019.11.16



# MIS–Endoscopy for lumbar disc disease and canal stenosis

---

**Sukumar Sura**

Department of Spine Surgery,  
Asian Spine Hospital, Hyderabad, India

1. Introduction .....	26
2. History .....	26
3. Interlaminar technique .....	27
3.1. Procedure .....	28
4. Spinal stenosis .....	29
5. Current indications .....	30
6. Conclusion and future .....	30
References .....	30

The aim of this chapter was to highlight the current evidence and status of Full Endoscopic Spine Surgery (FESS) and analyze the effectiveness of full endoscopic surgeries for symptomatic disc herniations, lumbar canal stenosis, thoracic, cervical decompressions in comparison with the conventional approaches. The advantages Endoscopic Spine procedures offer less morbidity, Less pain in post-operative period, early mobilization and safer complication profiles. Endoscopic decompressions has been utilized in case of degenerative spinal stenosis. As technological innovation continues to facilitate reproducible surgical technique and expand the indications for use, FESS technique will provide surgeons with a more powerful and less morbid approach to spinal pathology that ultimately elevates the standard of care when treating our patients.

## 1. Introduction

Endoscopic techniques in spine have seen over 30 years of evolution and innovation, however, early usage of these techniques largely focused on transforaminal lumbar discectomy. Minimally invasive spine procedures have undergone rapid development during the last decade. Efforts to decrease muscle injuries during prolonged retraction, avoid significant soft tissue stripping and minimize bony resection are surgical principles that are employed to prevent iatrogenic instability and provide patients with decreased post-operative pain and disability. Full Endoscopic spine surgery (FESS) promises to be the next paradigm shift in the field of minimally invasive spine surgery (MISS). FESS represents an added tool for the spine surgeon to provide targeted access to spinal pathology utilizing these principles and adding better image quality under bloodless field.

## 2. History

However, the use of endoscopy has been slow to develop, partly due to un-familiarity with the technique and clinical benefits. Studies of its safety and efficacy are beginning to surface and full endoscopic spine procedures are now being performed in spine centers around the world. It was in the early 1970s when endoscopic spine surgery gained a renewed interest, which started with “blind” nucleotomy or discectomy. A technique for fluoroscopic-guided Percutaneous non-visualized discectomy under local anesthesia was described by Hijikata, 1975 (1) and Kambin, 1989 (2) and. Using specialized cannulas and instruments without endoscopic visualization, these techniques represented “intra-discal” indirect decompression procedures to address posterolateral disc herniations via removal of the posterior one third of the nucleus pulposus. Kambin conducted numerous cadaveric studies to describe the boundaries of a safe working zone for posterolateral access to the disc space (2). He defined Kambin’s triangle, a theoretical triangle for safe access into the disc over the posterolateral disc: the hypotenuse is the exiting nerve root, the base (width) is the superior border of the caudal vertebra, and the height is the dura/traversing nerve root. The triangle is loosely covered by adipose tissue and small superficial veins as well as suspensory.

Ligaments tethering the neural structures (Figure 1).

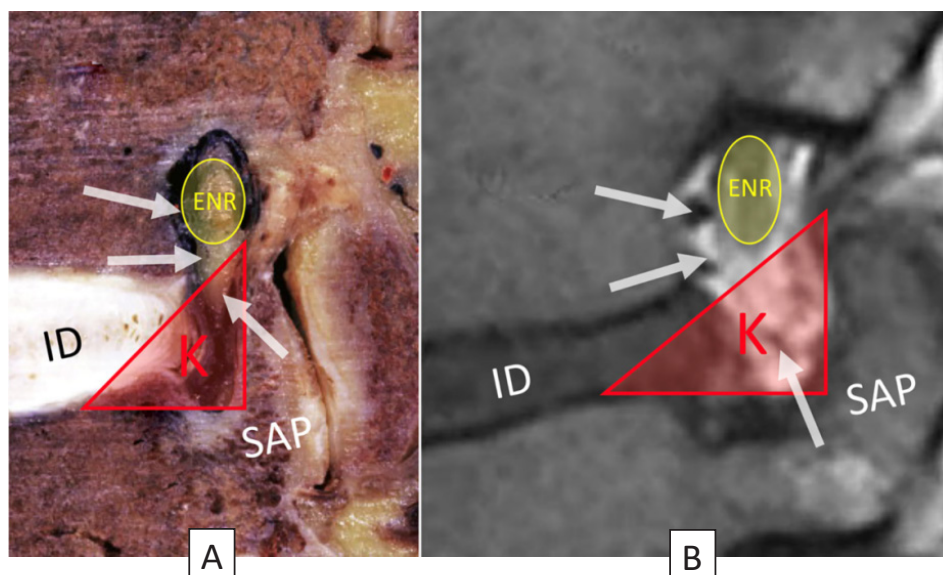


Figure 1 | (A) Depicts a sagittal cross-sectional image of a cadaveric specimen illustrating Kambin's triangle (K); (B) depicts a sagittal cross-sectional image from a T2-weighted MRI illustrating Kambin's triangle (K). SAP -superior articular process of the caudal vertebrae, ID -intervertebral disc, ENR -exiting nerve root and the gray arrows -contents of the foramen including perineural fat, perineural vessels and foraminal ligaments.

Schreiber, Suezawa, and Leu were the first to have the idea to perform this Percutaneous nucleotomy under visual control using and endoscope (discoscopy).

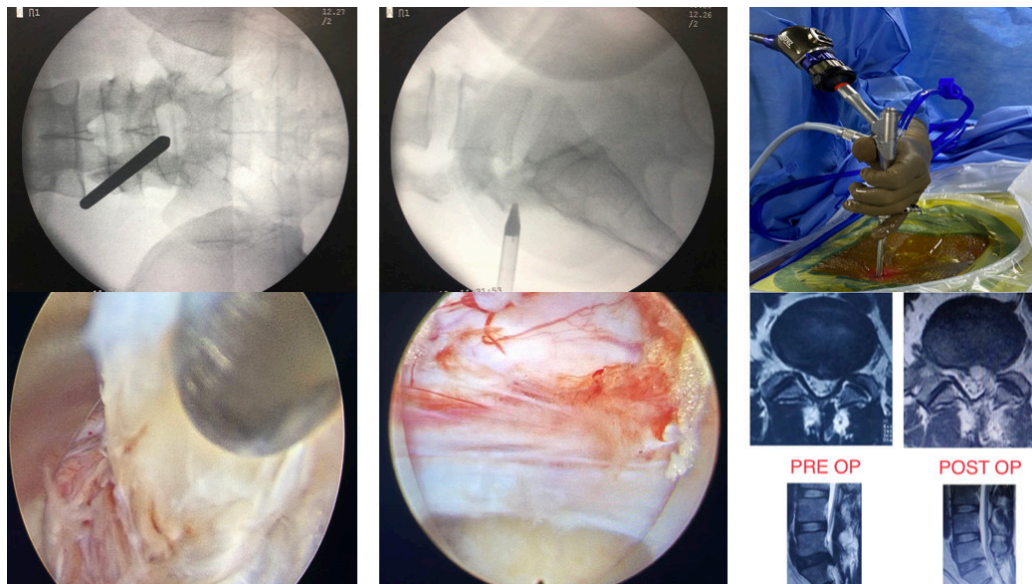
### 3. Interlaminar technique

While transforaminal endoscopic surgery was slowly evolving, the initial learning curve and lack of access to expert training resulted in slow adoption. Concurrently, the development of the tubular retractor system by Destandau (3) and Foley in the late 1990's, heralded a new era of minimally invasive techniques utilizing an interlaminar window. The use of the microscope soon supplanted the endoscope among most spine surgeons. At the beginning of the 2000s it was Sebastian Rutten, a German spine surgeon, who adopted this technology and applied it for interlaminar endoscopic approaches. This significantly enlarged the indication spectrum of this technology.



### 3.1. Procedure

The posterior interlaminar approach is utilized predominantly at the L5–S1 level and sometimes to L4–L5 levels also. Patient is positioned in the prone position on a well cushioned and supportive radiolucent frame or bolsters under GA. An AP view of the desired level is marked and a second line is made just lateral to midline. At this intersection a small 4 mm incision is performed and a two hole obturator is placed down to the level of the ligamentum flavum (LF). The working cannula and endoscope is then placed. Note a guide wire is not utilized. Careful dissection through the LF is then performed. The lateral edge of the nerve root is identified by performing a partial facetectomy as needed. The working cannula is then rotated and the nerve is gently retracted. Discectomy can then be performed. Current interlaminar endoscopic techniques mirror those of tubular techniques with the added advantage of improved visualization and more targeted placement due to the manoeuvrability of a narrow endoscope and the ability to manipulate the field of view with optical rotation of the endoscope. For example, endoscopic unilateral laminotomy for bilateral decompression

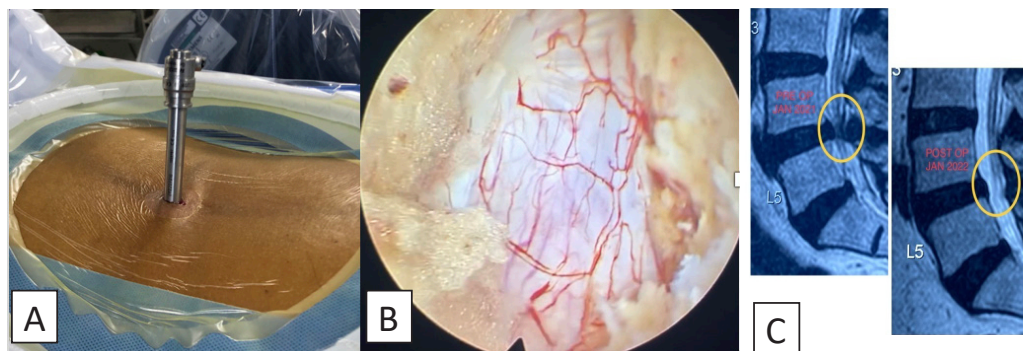


**Figure 2** | Full endoscopic discectomy: interlaminar route. (A) Dilator placement in AP view, (B) dilator placement in lateral view, (C) extruded Disc fragment removed, (D) decompressed nerve root well seen, (E) interlaminar scope and hand position, (F) pre and post-operative MRI T2WI showing removal of the fragment.

(ULBD) for lumbar spinal stenosis allows for excellent ipsilateral facet joint preservation given off-angle visualization and the ability to tilt the small diameter endoscope out into the lateral recess. These features allow for generous decompression of the nerve root beyond the caudal index level pedicle when performing a posterior endoscopic cervical foraminotomy. Interlaminar techniques can currently be performed in the cervical, thoracic and lumbar spine.

## 4. Spinal stenosis

Stenosis can be congenital or acquired. Only 9 % of cases result from congenital etiologies such as short pedicles, vertebral wedging, segmentation failure, achondroplasia. Acquired stenosis occurs from trauma, degenerative changes, iatrogenic causes. Degenerative changes are common in elderly population where there is central and lateral recess stenosis from disc herniations, LF hypertrophy and facet hypertrophy.



**Figure 3** | Full Endoscopic stenosis surgery. (A) Stenosis sheath insertion, (B) Endoscopic decompression ipsilateral and over the top decompression done, (C) MRI T2WI showing decompression of the canal achieved in sagittal imaging, (D) axial T2WI MR showing comparison of pre and post-operative decompression (E) X-ray images showing widened canal post-decompression.

The commonest surgery for the stenosis in past was traditional open laminectomy and decompression with or without instrumentation. In recent past Endoscopic stenosis decompression has become the standard norm for the decompression and the results are as equivalent as the traditional surgeries but having advantage of least invasive technique and early recovery. Here are some of the



examples and comparison of pre and post-operative MRI images in patients with stenosis.

## 5. Current indications

- (1) Removal of all types of disc herniations including difficult cases and recurrent disc Herniations-
  - (a) Medial disc herniation
  - (b) Down migrated disc herniations
  - (c) Bilateral disc herniations
  - (d) Recurrent disc herniations
  - (e) Calcified disc herniations.
- (2) Decompression of central and foraminal spinal stenosis.
- (3) Decompression of lateral recess stenosis.

## 6. Conclusion and future

Endoscopic discectomy and stenosis decompression is showing equivalent results as compared to microscopic and open decompression. In the context of an invasiveness and complexity index, the role of endoscopic spine surgery can be better conceptualized and understand its true utility in the treatment of spinal pathology to allow for more widespread adoption. Although there is a learning curve associated with these procedures, we believe that endoscopic techniques offer a more powerful and less morbid approach to spinal pathology that ultimately elevates the standard of care when treating our patients. The acceptance of this technology is high among young surgeons, and zeal to learn more creates opportunity for the hospitals, and the scientific societies to develop learning- and training-concepts to shorten learning curves and to improve technical quality and clinical outcomes. Further we need large scale RCTs to confirm the advantages of Full Endoscopic Spine Surgery.

## References

1. Hijikata S, Yamagishi M, Nakayma T. Percutaneous discectomy: a new treatment method for lumbar disc herniation. *J Toden Hosp.* (1975) 5:5–13.
2. Kambin P, Schaffer J. Percutaneous lumbar discectomy. Review of 100 patients and current practice. *Clin Orthop Relat Res.* (1989) 24–34.
3. Destandau J. A special device for endoscopic surgery of lumbar disc herniation. *Neurol Res.* (1999) 21:39–42.

# Treatment of Lumbar degenerative disc disease and lumbar stenosis-tubular retractor minimally invasive spine surgery

---

**Savitr Sastri BV**

Neurosurgeon and Minimally Invasive Spine Surgeon,  
KIMS Hospital, Kondapur, Hyderabad, Telangana, India

1. Introduction.....	31
2. Tubular retractor microdiscectomy–Posterolateral disc prolapse.....	33
3. Far lateral disc prolapse .....	36
4. Lumbar canal stenosis–Unilateral, over the top decompression.....	39
5. Complications of tubular retractor surgery and complication avoidance.....	41
References .....	42
Additional Suggested Reading.....	42

## 1. Introduction

Lumbar disc herniations are one of the commonest diseases treated by spine surgeons. Since its description as the cause of radiculopathy by Dandy, and Mixter and Barr in the 1930, there has been a substantial advancement in the understanding of the pathology of herniated lumbar disc disease and in the surgical management.

Love and Walsh in their series of 300 patients described the inter-laminar, extradural discectomy, which is the precursor to modern open lumbar discectomy.

Yasargil and Caspar are credited with microscopic discectomy and the first minimally invasive lumbar discectomy via a medial facetectomy and flavectomy.

Foley and Smith described the first microendoscopic discectomy in 1997, and the second generation of their device is the tubular retractor system currently in use today.(1) (MetrRx, Medtronic).

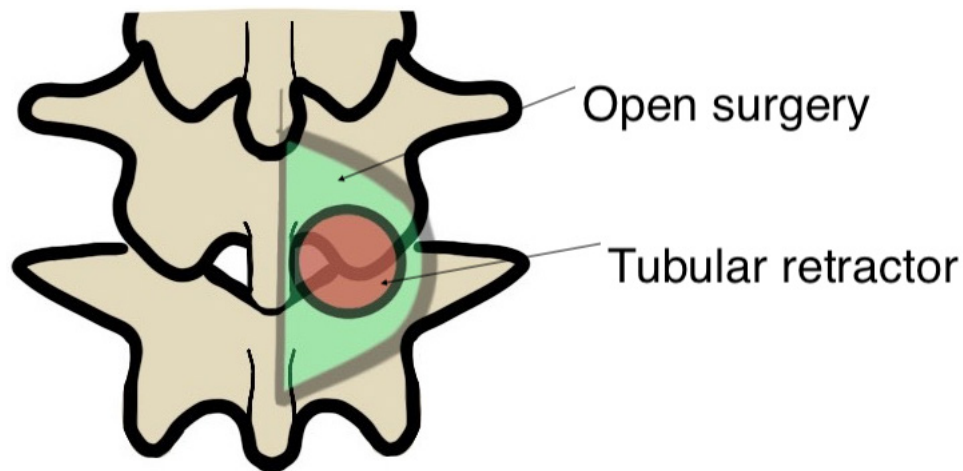
The principle underlying minimally invasive lumbar spine surgery has been outlined in previous chapters; however, a reiteration is mandated in this section. Luis Manuel Tumilan in his excellent textbook describes what he terms “Casper’s Ratio.” This is the ratio of the area of the surgical target over the area of surgical exposure. Ideally, the closer this is to 1, the less invasive the surgery with minimal collateral damage to surrounding structures.(2)

The role of the multifidus muscle in spine stability is well documented and the stripping of this muscle from its attachments causes ischemic damage. The second reason for muscle injury is the use of powerful retractors for prolonged periods of time, resulting, again, in ischemia.

The use of tubular retractors has two main advantages with respect to muscle integrity. The first is that there is no detachment or significant cutting of the muscles, since they are split along the fibers via serial dilatation. The second is that the tubular retractor does not require to compress the muscle in order to maintain its position (unlike conventional retractor blades), since it is table mounted. In addition, the forces are distributed all along the wall of the cylindrical retractor as opposed to the unidirectional force vectors in a hemilaminectomy retractor blade.

These lead to the obvious immediate benefits of minimally invasive spine surgery, which are reduced postoperative pain, reduced infection rates, and a consequent earlier return to normal activities.

Figure 1 shows the difference in exposure in a conventional midline exposure for a unilateral discectomy vs. the tubular retractor.



**Figure 1** | Difference in exposure of conventional open approach for posterolateral discectomy (green) vs tubular discectomy (red).

## 2. Tubular retractor microdiscectomy– Posterolateral disc prolapse

Tubular retractor microdiscectomy can be performed for all types of herniated lumbar discs. Central, paracentral, foramina, extraforaminal, and extruded discs with upward or downward migrated fragments.(3)

The steps of surgery are common for these procedures and they vary largely with where the retractor is docked and how much exposure is required to retrieve the disc fragments.

The surgical equipment required for minimally invasive tubular retractor spine surgery varies slightly from open surgery to accommodate to the limited exposure and vision.

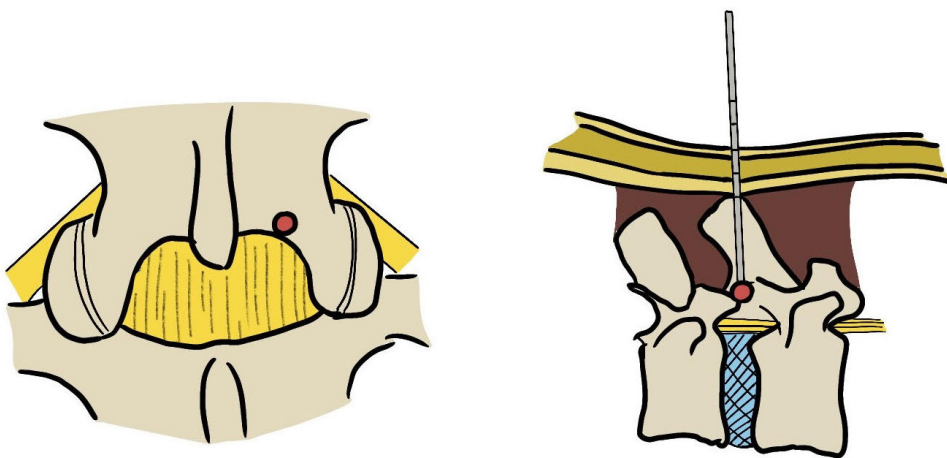
These surgeries are performed with the aid of an operative microscope. The retractor itself has a set of dilators, with or without a Kirschner wire, various retractors of commonly 16, 18, and 22 mm in diameter, of various lengths. There is also an articulating arm that fixes onto the operating table and holds the retractor in place once it is inserted.

The instruments, such as dissectors, probes, Kerrison punches, are usually bayoneted and longer than those used in conventional surgery. In addition, the drills used are usually the angled or curved hand pieces.

Patients are positioned prone on bolsters or in the knee-chest position, and most commonly under general anesthesia. This surgery can be done under epidural anesthesia as well but centers that do so are rare. Ideally, a Jackson table is used with the ability to take AP and lateral fluoroscopy images without any hinderance.

The exact level of disc prolapse is identified on lateral fluoroscopy. For a standard paracentral disc prolapse, a 2 cm skin incision is made 1.5 to 2 cm off the midline and the fascia is incised in line with the skin. The first dilator is introduced and advanced through the muscle to reach the bone of the lamina. This step needs to be done carefully to prevent inadvertent advancement of the dilator through the inter-laminar space, and to prevent injury to the dura or the nerve roots.

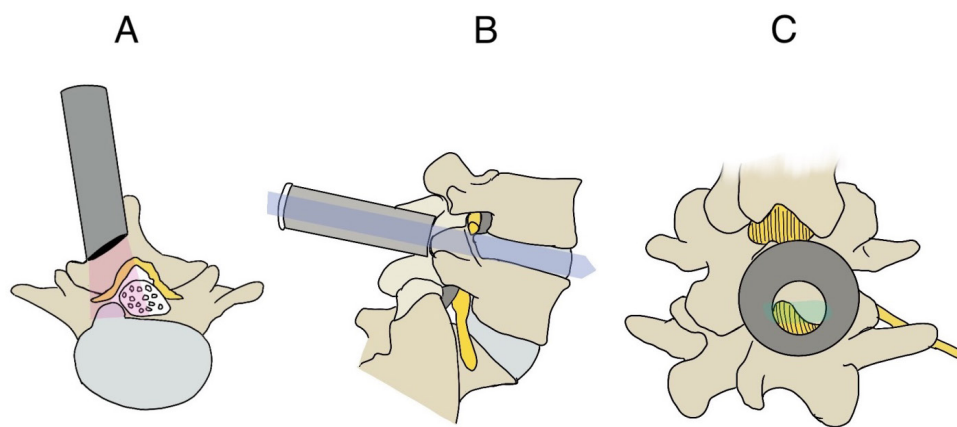
The lamina can be felt with the dilator tip and is identified by the abrupt fall off inferiorly and the laminar edge, by the gradual upslope toward the spinous process medially, and by palpating the facet laterally. The exact docking point is shown in Figure 2. It is important to use fluoroscopy at this point to confirm the spinal level of the dilator and that it is coaxial to the disc. Serial dilators are then inserted ensuring that the tips of the dilators stay in contact with the lamina. This prevents the ingress of muscle tissue, also known as muscle creep. For a standard discectomy an 18 mm retractor is usually sufficient. The length of the retractor is determined by the depth markings on the larger dilators. The retractor is placed over the final dilator and attached to the table arm. While there is no rigid rule as to the orientation of the retractor, it's often more convenient



**Figure 2** | First docking point for posterolateral discectomy seen in bird's eye and lateral view.

to position the handle of the retractor exactly opposite the surgeon, i.e., toward the midline.

At this point a final confirmatory fluoroscopy is done and the microscope brought in. Figure 3 shows the final position in axial, lateral, and bird's eye view. The remaining steps are performed identical to an open discectomy, except through the tubular retractor. The lower lamina and medial facet are drilled out and the ligament flavum excised. The nerve root and dural tube are identified and gently freed from the underlying disc and retracted. The discectomy can then be performed as usual. The surgery is deemed complete when all the disc fragments are excised and the root confirmed free from compression. Hemostasis is attained via conventional methods and the retractor may then be removed. The fascia is closed, and the author has found the stout 1/2 circle laparoscopy port closure needles with Vicryl to be particularly useful for this task. The subcutaneous and skin incisions are closed after infiltration with a local anesthetic. Typically, no urinary catheter is placed and the patients encouraged to walk soon after recovery from anesthesia.



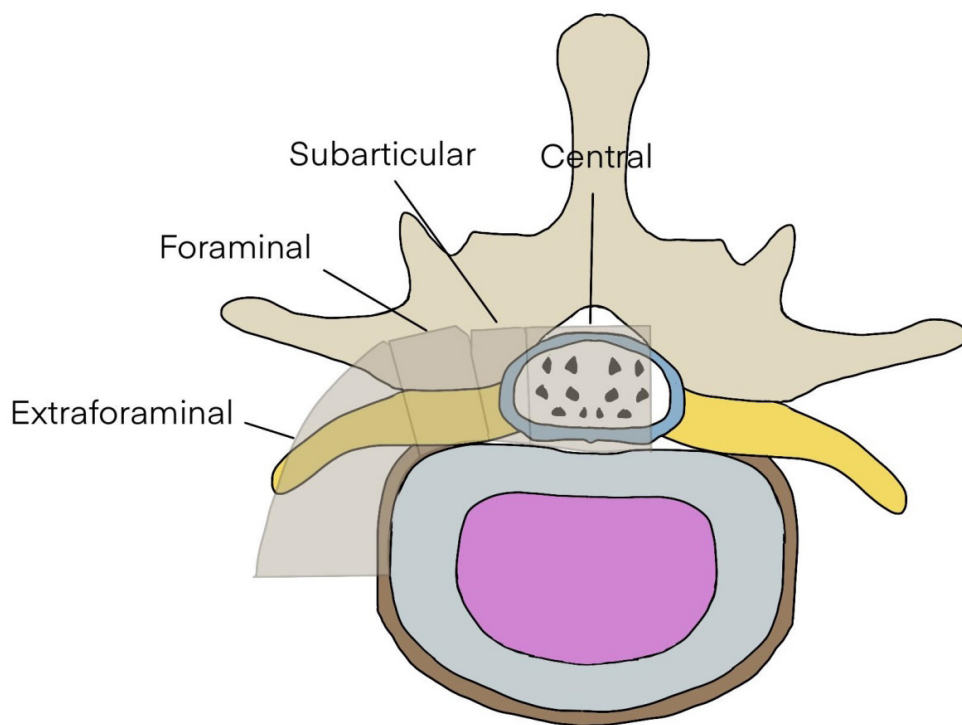
**Figure 3** | Final retractor position in panels A - axial, B - lateral and C - bird's eye view. C- green overlay represents the level of the disc.

For disc fragments that may have migrated, the initial docking point and more importantly the angle of the first dilator, and thus the retractor, may be altered based on the preoperative imaging. If, however, the visualisation is not adequate and an adjustment is required, a technique called “wandling” may be employed. Here, the final dilator is reinserted through the retractor and the table arm loosened and the dilator may be used as a wand to change the direction

of the retractor. Again, it is important to confirm the position with fluoroscopy.

### 3. Far lateral disc prolapse

Far lateral disc prolapses or extraforaminal herniations (figure 4) pose a significant surgical challenge for open spine surgery. The amount of muscle dissection required if using a conventional midline approach makes this surgery extensive and morbid with significant post-operative pain and long term muscle damage. A paramedian approach of Wiltse has also been described to tackle extraforaminal disc bulges but again due to the bulk of the paraspinal muscles, requires a longer incision and substantial muscle retraction (4). The tubular retractor if used from a modified docking point provides adequate exposure with minimal tissue damage.



**Figure 4** | Various zones of disc prolapse, central, paracentral or subarticular, foramina, and extraforaminal.

The patient positioning and other preliminary steps being the same, after confirmation of the level of pathology, a skin incision is made 2.5 to 3 cm off the midline. The initial dilator is introduced



and the lateral border of the lamina, the pars interarticularis, and the inferior articular process are identified. The dilator is docked at the root of the inferior articular process just medial to the outer border of the lamina (Figure 5). Once the retractor is placed, the lateral lamina, transverse process, and the upper and outer quadrant of the facet should be visualized. Further exposure is obtained by drilling the outer edge of the lamina and the lateral part of the facet. The intertransverse membrane is divided and the exiting root identified and maybe mobilized superiorly to expose the herniated disc, which can then be removed with pituitary forceps.

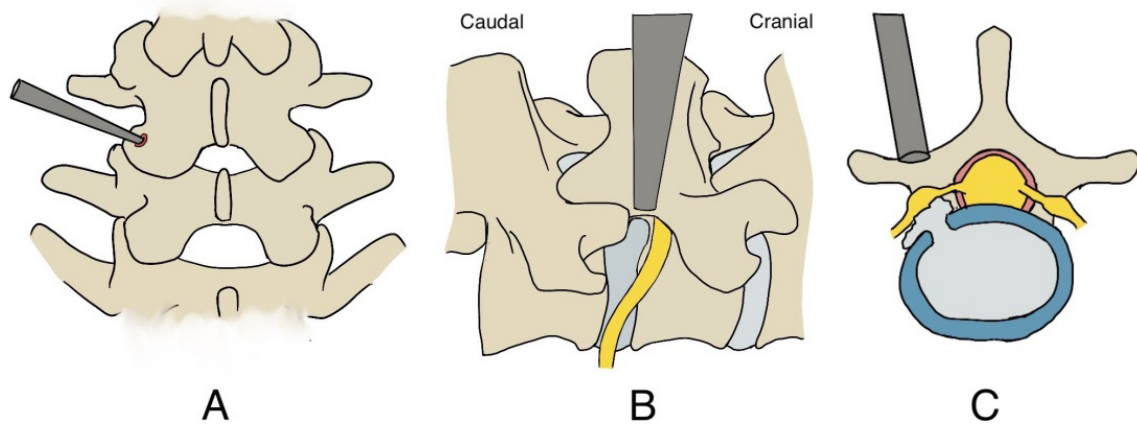
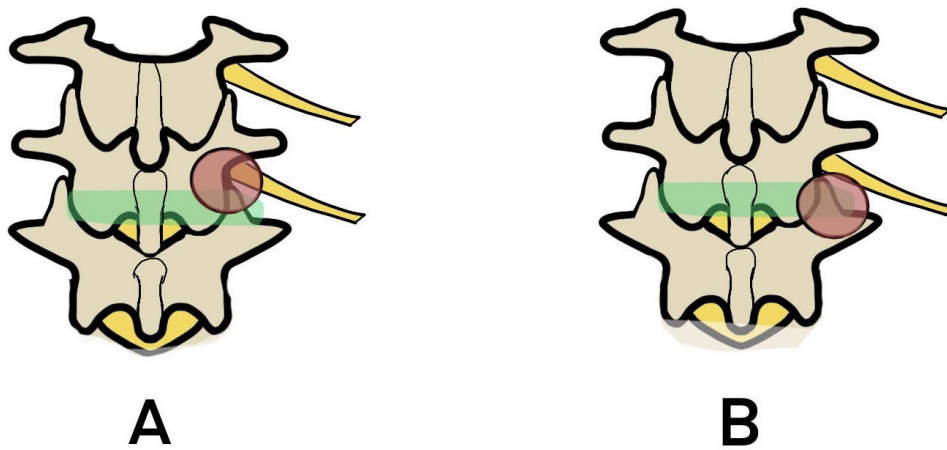


Figure 5 | Initial docking points for far lateral/extraforaminal disc prolapse.

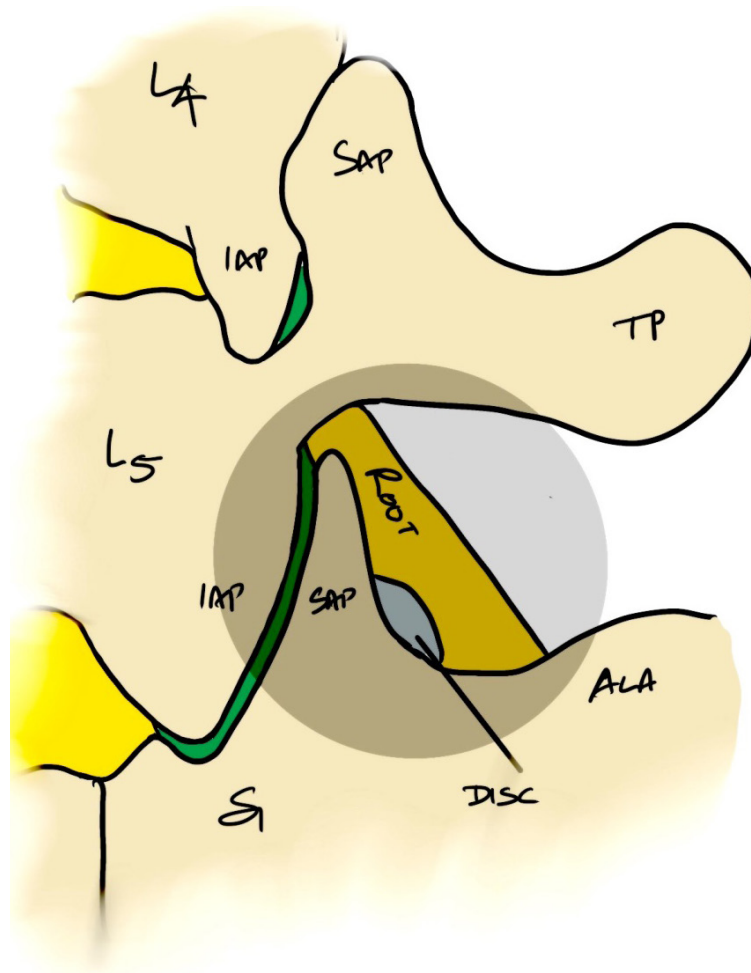
Variations of docking points have been described in literature with some authors proposing the lower transverse process and the initial identification point and docking the retractor on the lower facet joint (Figure 6). Dissection is then carried out superomedially to identify the herniated disc without having to manipulate the nerve root.(5)

The L5-S1 extraforaminal disc prolapse is another instance where this surgical technique is of great value. The L5 vertebra has a broader pedicle width and the L5 S1 facet joint is larger than the ones above. In addition, the space between the L5 transverse process and the sacral ala is narrow. The iliolumbar ligaments in the region further restrict the space available for the nerve root, and finally the iliac crest may obstruct access. In order to access the extraforaminal surgical target in these cases the retractor is docked lateral to L5S1 facet (Figure 7). Following this, drilling is done from the base of the





**Figure 6** | Alternative docking point (B) for far lateral disc when compared to the conventional point (A).



**Figure 7** | Docking and exposure for L5S1 extraforaminal disc prolapse. SAP - Superior articular process, IAP - Inferior articular process, TP - transverse process. Shaded region is the exposure following placing the retractor.

S1 superior articular facet, over its lateral margin, and the lower part of the L5 transverse process. Rarely, the upper part of the sacral ala may also be drilled for greater access (6).

#### **4. Lumbar canal stenosis–Unilateral, over the top decompression**

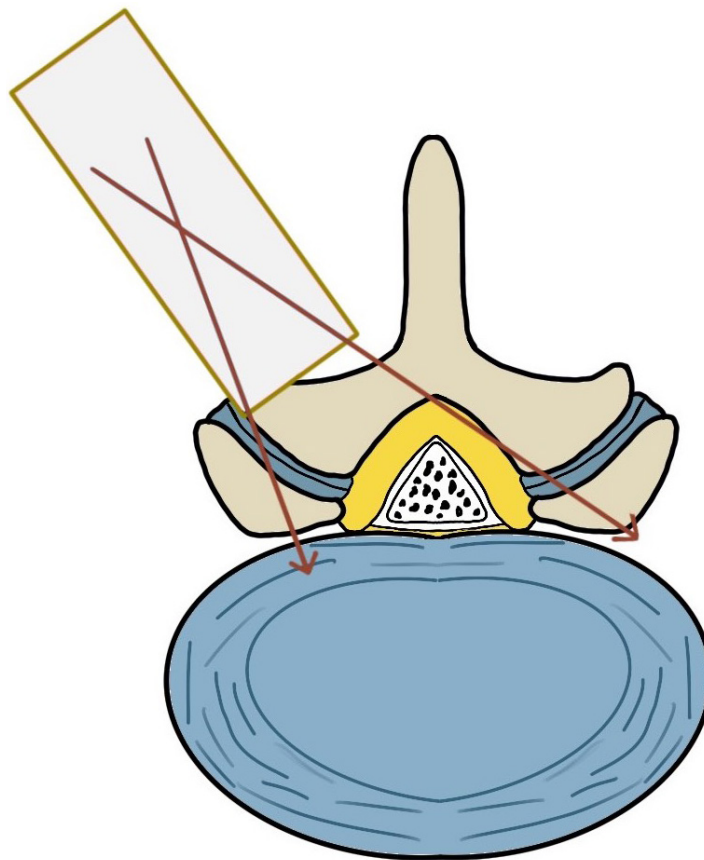
The role of tubular retractors in lumbar canal decompression began after description of unilateral approaches for bilateral decompression by Young in 1988, and a modification of the approach by McCulloch in 1991 (7,8). The traditional open treatment for degenerative canal stenosis is typically a wide laminectomy with sacrifice of the midline structures and the muscle attachments. This typically leads to a higher incidence of iatrogenic instability, which in turn requires either primary fixation, or a second surgery to address the problem. Degenerative stenosis often has a component of degenerative spondylolisthesis which is worsened with conventional approaches.

The minimal invasive surgical technique is tailored to perform adequate decompression of the nerve roots and the thecal sac, while maintaining spinal stability. The multifidus muscle is only split on the ipsilateral side and the contralateral muscle attachments are preserved. Midline structures such as the interspinous and supraspinous ligaments are protected. This results in a lower incidence of iatrogenic instability. MIS decompression is recommended for patients with degenerative canal stenosis with stable spondylolisthesis up to grade 1. Preoperative evidence of instability, on dynamic X-rays, is a contraindication for decompression alone.(9)

MIS decompression uses the technique of wandng, which has been previously described to be able to visualize the opposite root and lateral recess. This is facilitated by aggressive drilling of the medial part of the lamina and the base of the spinous process.

The surgical steps are as follows. Following induction, positioning, and draping as per the usual fashion, the level is confirmed on fluoroscopy. The unilateral approach is usually from the more symptomatic side, and if there is no such lateralisation of symptoms, it is the surgeon's preference. An incision is made 1.5 cm off the midline and the tubular retractor is placed and anchored in the same spot as for a conventional MIS discectomy. The ipsilateral lower border of the lamina, medial third of the facet and upper border of

the lamina of the vertebra below (if required) are thinned out by a high-speed burr and the remaining bone removed via 2 mm Kerrison rongeurs. The ligaments flavum is then dissected in layers till it can be opened and the epidural fat confirmed. The ligament can be dissected free off the underlying dura by means of ball tipped, blunt dissectors and then be excised. By angling the microscope to view laterally and rotating the bed towards the surgeon, the ipsilateral lateral recess can be visualised and decompressed with 1 and 2 mm punches, taking care to avoid excessive pressure on the nerve root. The ipsilateral lamina may be further drilled to visualise the exiting and traversing roots at the target level. Once the roots are confirmed free, the retractor may then be wanded medially to point towards the contralateral recess. Some surgeons prefer to use a beveled retractor for the contralateral decompression. With either tube, the next step is to drill out the lower part of the spinous process, keeping the ligamentum flavum intact, to protect the dura. It is also more convenient



**Figure 8** | Exposure and angulation for over-the-top decompression of the contralateral root.

to rotate the table away from the surgeon and angle the microscope to attain proper sight of the opposite side. Following this the dura can be protected with an instrument or a cottonoid and the soft tissue decompression carried out with long Kerrison's punches. Decompression of contralateral exiting and traversing roots may be done and the adequacy of the procedure assessed with blunt tipped probes, passed along the roots.

Hemostasis is then attained, and the incision closed in layers following infiltration with a local anesthetic. Patients are typically allowed to walk 5–6 hours after surgery and discharged within 24 hours.

## **5. Complications of tubular retractor surgery and complication avoidance**

The complications of tubular minimally invasive surgery are similar to open discectomy, the most common being inadvertent dural tears. These are ideally primarily repaired using sutures or clips or in some cases autologous fat or muscle, or dural substitutes, with or without fibrin glue. The absence of a dead space within the muscles on removing the retractor ensures the chances of a persistent CSF fistula are little to none.

The other commonly noted problem with surgeons early in their minimally invasive career is passing the first dilator too deep, with potentially disastrous results, or in the wrong direction altogether. Avoiding the use of K-wires is essential to prevent dural damage in the first step of surgery and use of fluoroscopy to confirm the position of the first dilator, the final tube position, and following any wanding manoeuvres.

With improved surgical microscopes and instrumentation the early concerns of longer operating time, residual or missed fragments and inadequate decompressions are no longer valid with minimally invasive spine surgery. There is a requirement for training and reorientation of surgeons to minimally invasive surgery since conventional teaching relies on the midline approach. Operating through a narrow corridor also requires practice with longer, bayonetted instruments and the ability to visualise the anatomy around the retractor which is not seen. This ability and technique, as they improve with time will provide patients with fewer complications, less post-operative pain and disability and a sooner return to normal life.

## References

1. Foley KT, Smith MM, Rampersaud YR. Microendoscopic approach to far-lateral lumbar disc herniation. *Neurosurg. Focus* (1999) 7:e5.
2. Tumialán LM. *Minimally invasive spine surgery a primer*. New York, NY: Thieme (2020).
3. Perez-Cruet M, Smith M, Foley K. Microendoscopic lumbar discectomy. In: Perez-Cruet M, Fessler R editors. *Outpatient spinal surgery*. St. Louis, MO: Quality Medical Publishing, Inc (2002). p. 171–83.
4. Wiltse L, Spencer C. New uses and refinements of the paraspinal approach to the lumbar spine. *Spine* (1988) 13:696–706.
5. Siu TLT, Lin K. Direct tubular lumbar microdiscectomy for far lateral disc herniation: a modified approach. *Orthop. Surg.* (2016) 8:301–8. doi: 10.1111/os.12263
6. Lee S, Kang JH, Srikantha U, Jang I, Oh S. Extraforaminal compression of the L-5 nerve root at the lumbosacral junction: clinical analysis, decompression technique, and outcome. *J. Neurosurg. Spine* (2014) 20:371–9.
7. Young S, Veerapen R, O’Laoire S. Relief of lumbar canal stenosis using multi-level subarticular fenestrations as an alternative to wide laminectomy. *Neurosurgery* (1988) 23:628–33.
8. McCulloch J. Microsurgical spinal laminotomies. In: Frymoyer J editor. *The adult spine: principles and practice*. New York, NY: Raven Press, Ltd (1991). p. 1821–31.
9. Ozgur BM, Berta SC, Nguyen AD. Discectomy and laminectomy. In: Ozgur BM, Benzel E, Gerfin S editors. *Minimally invasive spine surgery*. Berlin: Springer (2009). p. 115–20.

## Additional Suggested Reading

*Minimally Invasive Spine Surgery: Advanced Surgical Techniques*. Kern Singh, Alexander R Vaccaro Ed. Jaypee, 2016  
*Minimally Invasive Spine Surgery A Primer*. Luis Manuel Tumialán. Thieme, 2020

# Minimally invasive spine surgery for lumbar fusion

**Satish Rudrappa, Akash Hosthota,  
Baru Dhruvkumar Hiralal and  
Ramachandran Govindasamy**

Department of Neurosciences,  
Sakra World Hospital, Bangalore, India

1. Introduction .....	43
2. Indications .....	44
3. Pre-requisite for MIS.....	45
4. Surgical anatomy.....	45
4.1. Operative setup: positioning and instruments needed .....	46
4.2. Core steps of performing MISS TLIF .....	47
4.2.1. Percutaneous pedicle screw placement .....	47
4.2.2. Docking and landing .....	49
4.2.3. Facetectomy and neural decompression.....	49
4.2.4. End plate preparation and discectomy.....	52
4.2.5. Cage/graft placement.....	53
4.3. Complication and prevention (Table 2).....	57
4.4. Literature review .....	57
4.5. Special scenarios (Table 3).....	59
References .....	64

## 1. Introduction

Lumbar degenerative disc disease (LDDD) is a common cause of low back pain. For decades, posterior lumbar interbody fusion (PLIF) and transforaminal lumbar interbody fusion (TLIF) have been used as effective surgical methods for LDDD, such as lumbar spinal stenosis, lumbar disc herniation, spondylolisthesis, and lumbar instability (1, 2).

Posterior lumbar interbody fusion has evolved tremendously since Cloward (3) first described the procedure in 1952. In 1982, Harms and Rolinger (4) introduced the open TLIF, which has since become one of the most effective procedures for lumbar spinal fusion.

However, traditional open PLIF and TLIF are associated with iatrogenic injury of the paraspinal muscle, which could cause post-operative intractable low back pain (5). Although open TLIF is a well-established procedure, it is invasive and is reported to have complication rates of up to 25% (6). To reduce soft tissue injury and intraoperative blood loss, minimally invasive transforaminal lumbar interbody fusion (MIS-TLIF) was first proposed by Foley et al. (7) in 2002 (8, 9). Since its introduction, the MIS-TLIF has demonstrated fewer complications, less intraoperative blood loss, shorter hospital stays and recovery time, and less post-operative narcotic use with similar clinical outcomes and fusion rates compared with conventional open TLIF (10, 11).

Furthermore, MIS-TLIF has been associated with advantageous outcomes in obese patients (12, 13). The benefits of MIS-TLIF relative to open TLIF can be attributed to the principles of minimizing soft tissue disruption, minimizing destabilization of the spinal segment(s) for achieving the operative goal, and bilateral decompression via a unilateral approach. Nevertheless, MIS-TLIF is limited by a narrow operating space and it may be difficult for beginners to operate and view the deeper surgical field through the tubular retractor (14).

## 2. Indications

The greatest advantage of TLIF is that it can be done from any level of an unstable segment from L1 to S1 unlike other routes like ALIF/OLIF. The commonest indication for Interbody fusion is “Degeneration.”

- I. Degenerative spine:
  - (a) Low-grade spondylolisthesis
  - (b) Spondylolysis
  - (c) Lumbar canal stenosis
  - (d) Degenerative disc disease/ disc prolapses
- II. Post-surgery:
  - (a) Post-laminectomy instability
  - (b) Adjacent segment disease(c) Pseudo-arthritis.



- III. Infection:
  - (a) Spondylodiscitis
- IV. Trauma- post-traumatic instability

Contra-indications: There are no absolute contraindications and only a few relative ones:

- I. Severe osteoporosis- The safety of implants is endangered.
- II. High-grade spondylolisthesis.
- III. Collapsed disc space.

### **3. Pre-requisite for MIS**

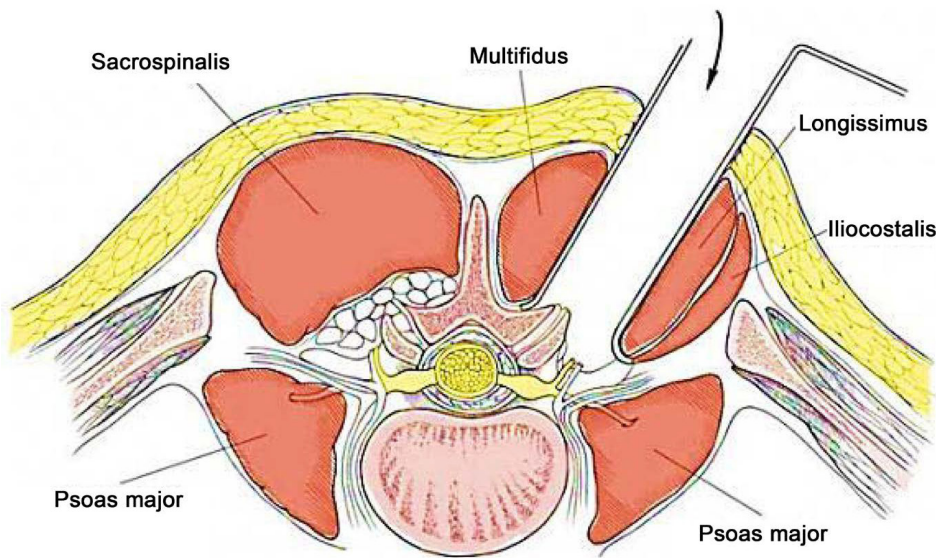
Over the last decade, there has been a paradigm shift toward MIS surgery. However, it is not the solution for all pathologies, and is very much dependent on technology. It is an approach to minimizing tissue damage, utilizing the narrow operating corridors. The surgical corridor should be adequately placed, sized, and cosmetic. The surgeon should be familiar with magnification, ambidextrous, and skillful with bipolar, monopolar, and micro suction to have a clean, bloodless field. The essential criteria for a satisfactory outcome are proper patient selection, adequate training, and excellent 3D orientation of anatomy and pathology as there is limited tactile feel and limited visualization due to the narrow corridor, which may result in an initial high complication rate and prolonged surgical time.

Understanding certain limitations of MIS is required for planning. For example, contra lateral exiting root visualization and direct decompression is not possible. There will be limited autologous graft for interbody bone grafting. Management of large dura tears requiring primary closure may be challenging. In cases of pedicle breach not having a good purchase due to osteoporosis, if the alternate path is taken rod insertion in multi-level will be demanding.

### **4. Surgical anatomy**

The lower back muscles (from ventral to dorsal) quadratus lumborum, erector spinae, and multifidus help in maintaining the lordosis of the lumbar spine. The paramedian natural plane is between the multifidus and longissimus part of the erector spinae muscle through which the tubes are passed (Figure 1). The advantage of the MIS approach over



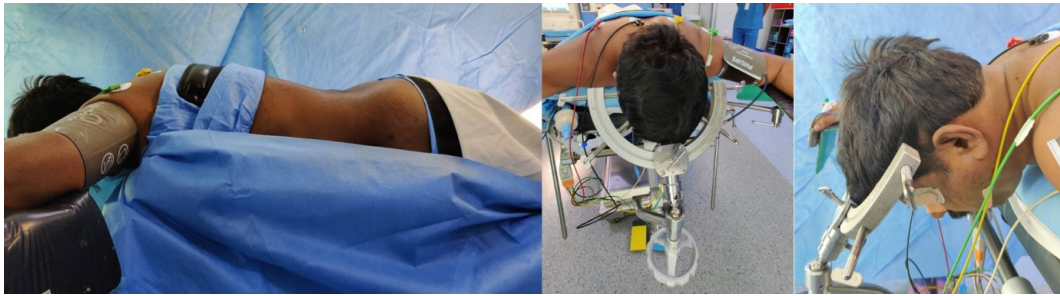


**Figure 1** | Pictorial representation of tube placement through the Wiltse approach.

open procedures in revision cases is because of this plane as it avoids the previous midline scar and laminectomy defects. This also spares the natural tension band of the posterior spine and also preserves the muscles on the contralateral side with minimal damage on the side of the procedure. The working corridor in TLIF is a “Kambin” triangle bound by thecal sac with traversing nerve root medially and exiting root with cephalad vertebra superiorly. The inferior border is made by the superior pedicle margin of the caudal vertebra.

#### **4.1. Operative setup: positioning and instruments needed**

The patient is positioned prone on a radiolucent table over the bolsters (to enhance lordosis) in such a way that there is no increase in intra-abdominal pressure. Arms are rested in abduction (90°) and placed on both sides with legs in mild knee flexion. Pressure points should be adequately padded and electrode placement for neural monitoring are fixed appropriately according to the level of the surgery. Electromyography monitoring is more useful during pedicle screw placements. The head is positioned on a hood or head pins, fixed to Sugita/Mayfield frames (Figure 2). Pins have certain advantages, as hoods are associated with increased pressure on the eyes, facial edema, lip injuries, and soft tissue abrasions, especially with monitoring motor evoked potentials which produce significant movement.



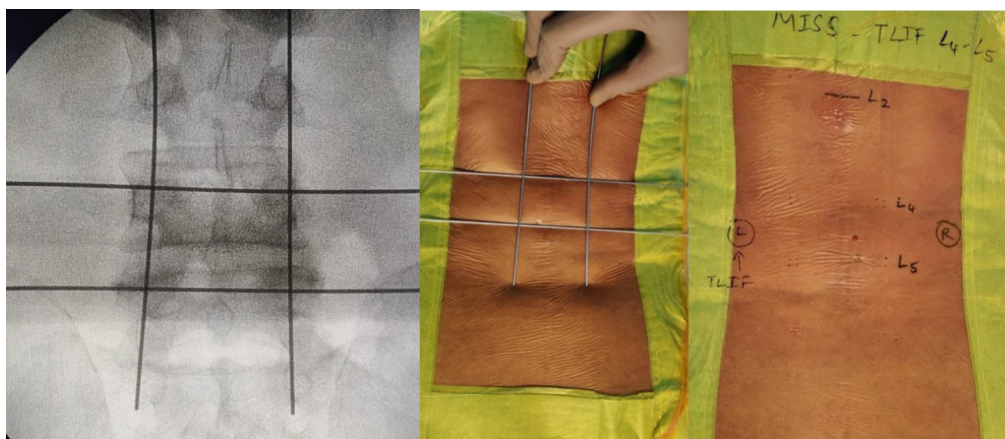
**Figure 2** | Positioning the patient with the head fixed on a Sugita pin frame.

## 4.2. Core steps of performing MISS TLIF

- A. Percutaneous pedicle screw placement
- B. Docking of tube and landing
- C. Facetectomy (symptomatic side) and neural decompression
- D. Discectomy and endplate preparation
- E. Graft/cage for fusion

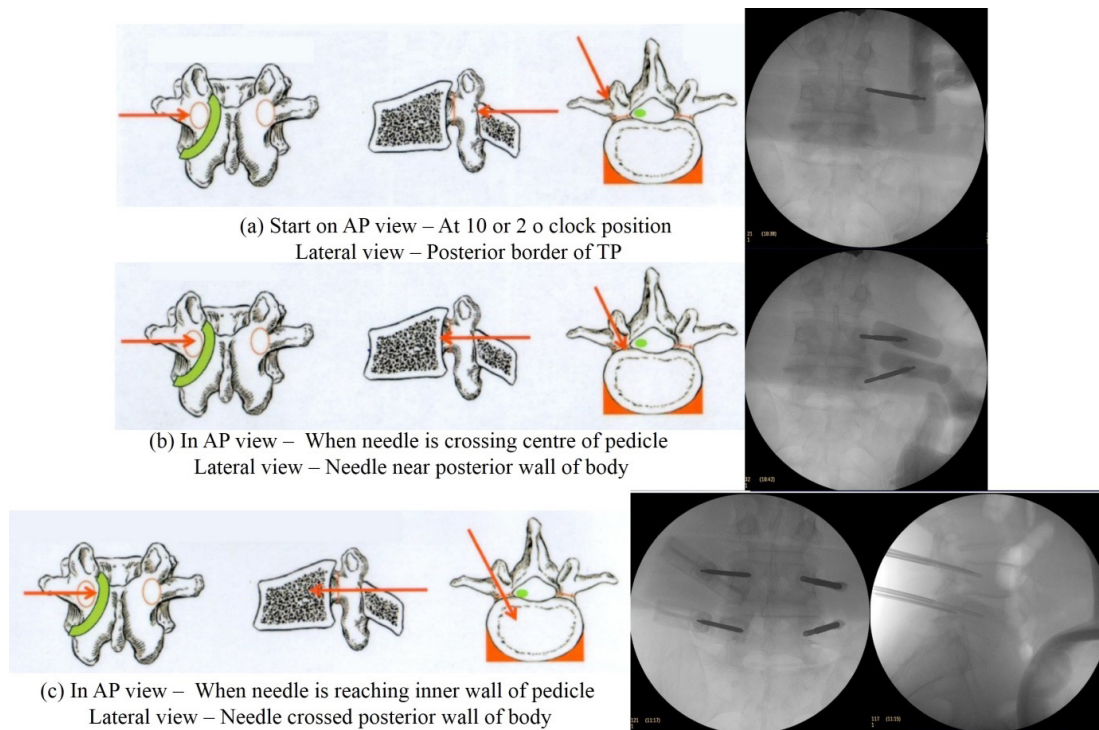
### 4.2.1. Percutaneous pedicle screw placement

First contra-lateral side screws are inserted followed by rod placement. Intra-op adjuncts like fluoroscopy/navigation are utilized for screw placement. In fluoroscopy the AP view is the key. An ideal AP view should have end plates parallel, the spinous process in midline and equidistant from both pedicles (Figure 3). Once dead AP view is obtained, 3 parallel lines are drawn, 1st along the midline spinous



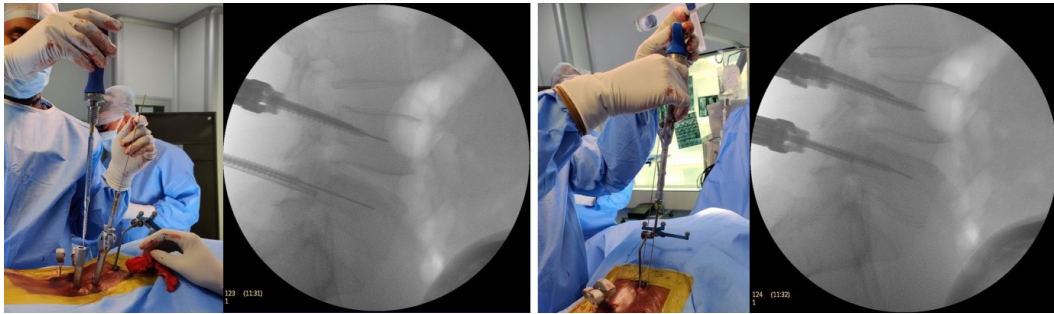
**Figure 3** | Co-linear fluoroscopic image showing linear endplate and skin marking corresponding to the lateral border of pedicles.

process and the other two along lateral borders of pedicles. A stab incision (approximately 2 cm) deep to the fascia is placed just lateral to the lateral border of the pedicle. Jamshedi needle is advanced until TP and facet joint encountered, taking entry at 10'o clock (Right side) and 2'o clock (Left side) (Figure 4A). This is advanced with 5 mm increments until the medial border of the pedicle is reached with the guidance of AP fluoroscopy (Figure 4B). At this point, the lateral X-ray should show the needle having crossed the pedicle-vertebral body junction (Figure 4C), if not there are chances of the medial breach with further advancement. Replace the Jamshedi with guide wires under lateral fluoroscopy to avoid the possibility of guide wire migrating anteriorly into the abdominal cavity. Cannulated MISS screws are placed over the guide wire after serial tapping on the contralateral side of TLIF (Figure 5). The tulips of both the screws should be at the same level (Antero-posteriorly and mediolaterally) for smooth placement of rods. Similarly, the ipsilateral screw trajectories are kept prepared with guide wires left in situ for future placement of screws after completion of facetectomy (Figure 6).

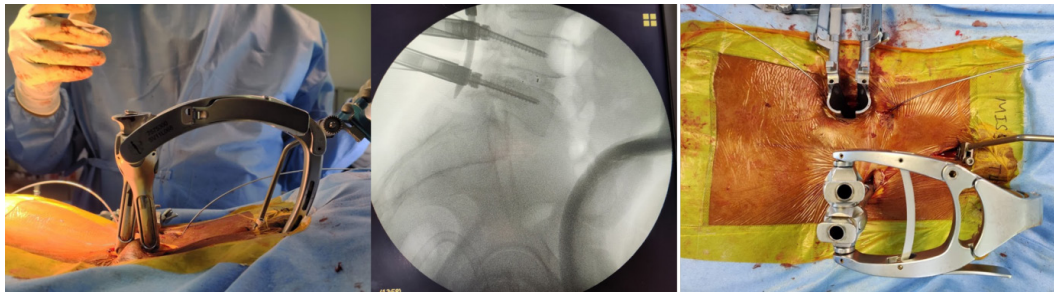

**Figure 4** | Serial images of Jamshedi needle insertion position for pedicle screw preparation (A) at the entry point, (B) at mid-pedicle, and (C) crossing the medial pedicle wall into the vertebral body.





**Figure 5** | Pedicle preparation with serial tapping followed by screw insertion over guide wires.



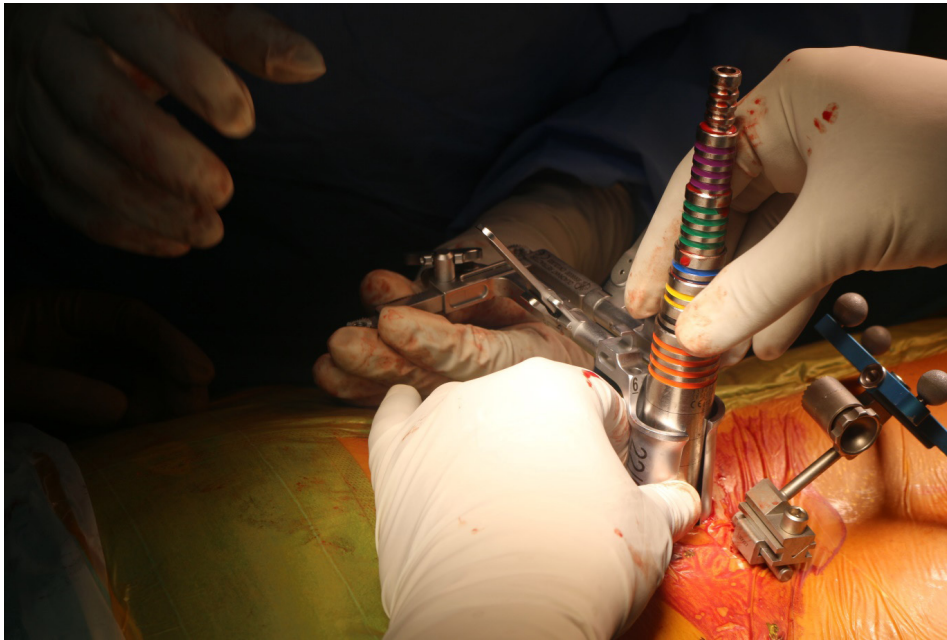**Figure 6** | Contralateral percutaneous rod placement, bent-guide wires on the ipsilateral side after tapping.

#### 4.2.2. Docking and landing

TLIF is usually performed from the symptomatic side, a side with radiculopathy, and the side with more symptoms in cases of bilateral symptoms. The incision is roughly 4–5 cm from the midline and 4 cm in length. An ideal landing should have the spino-laminar junction seen medially, and the facet joint laterally, and the upper end of pars should be visible cranially. For an efficient neural decompression, docking should be with the aforementioned landmarks visible. A guide wire at the level of the facet is to be removed followed by sequential use of increasing size dilators (maximum 22 mm) to splay the muscles and create space (Figure 7). Residual soft tissues are cleared with monopolar cautery to confirm the landmarks.

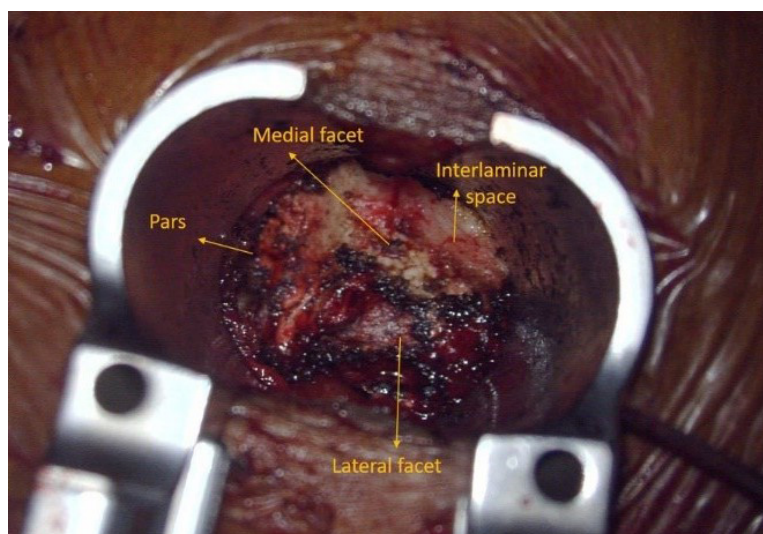
#### 4.2.3. Facetectomy and neural decompression

Before commencing with the decompression, the following landmarks should be reconfirmed: medial-spine-laminar junction, lateral-medial facet, cranially-pars, and caudal-superior lamina of inferior



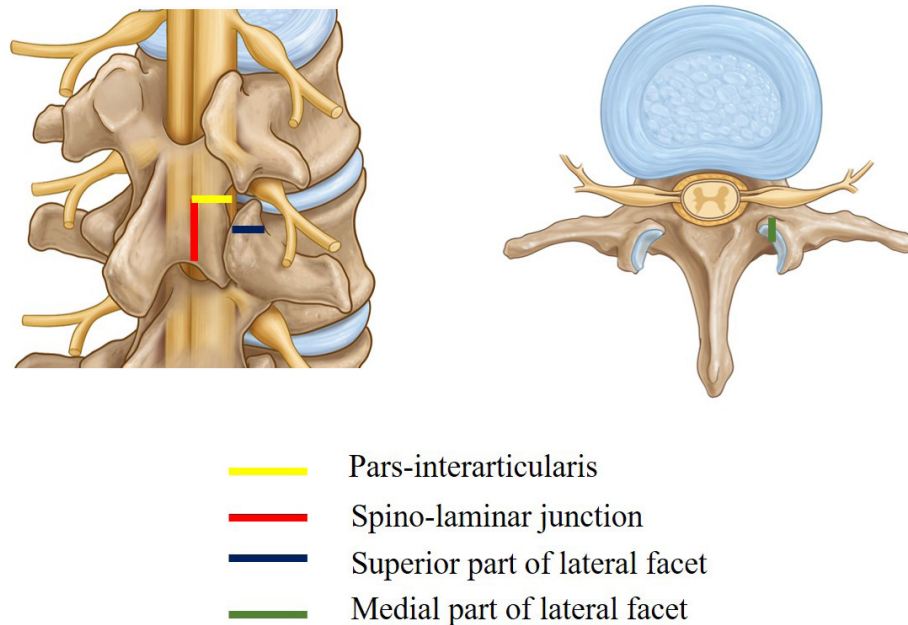
**Figure 7** | Tube placement after serial dilation of the Wiltse plane.

vertebrae (Figure 8). For central decompression, the medial facet is to be removed while for exiting root decompression, the superior aspect of the lateral facet is removed. To remove the medial facet as a single chunk to be useful as an autograft, we prefer the use of an osteotome. High-speed burr/Kerrison Rongeur or even high-precision bone scalpel can be used to do bony work. Once the medial facetectomy is completed, the superior aspect of the lateral facet

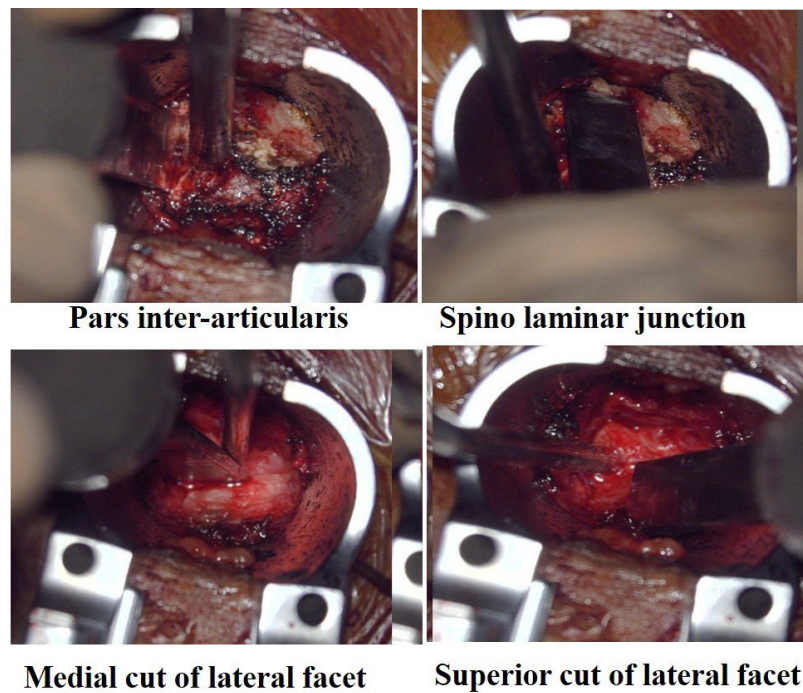


**Figure 8** | Visualization of bony elements through properly docked tubes.

is removed to serve 2 purposes, decompression of exiting nerve root as well as to create the lateral window for TLIF purpose (Figures 9, 10). Only after the bony work is completed, the ligament flavum removal should be commenced and is always preferred to be



**Figure 9** | Schematic representation of osteotomies of the facets.



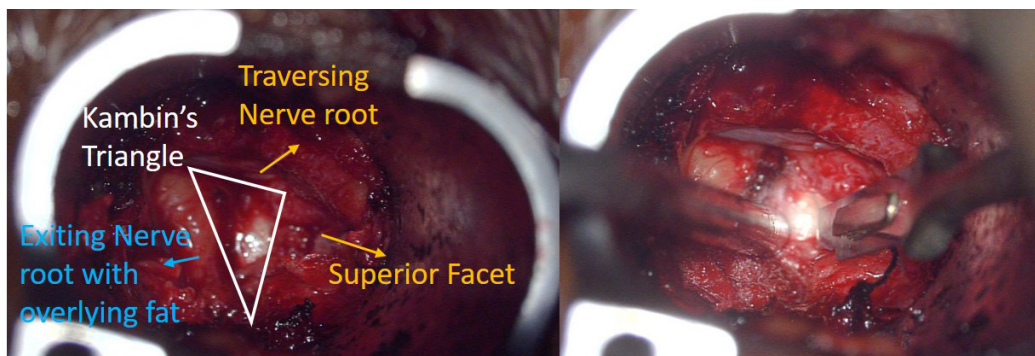
**Figure 10** | Microscopic images of serial facet osteotomies.



done under a microscope. The microscope helps in better achieving hemostasis while encountering epidural veins, identifying protective epidural fat pad, as well as delineating transverse and exiting roots, indirectly aiding the process of decompression. Tilting the tube medially and angulating the microscope with an over-the-top dura approach helps in the decompression of the contralateral side. The use of surgical loupes can be a cost-effective substitute for a microscope and is used by many surgeons.

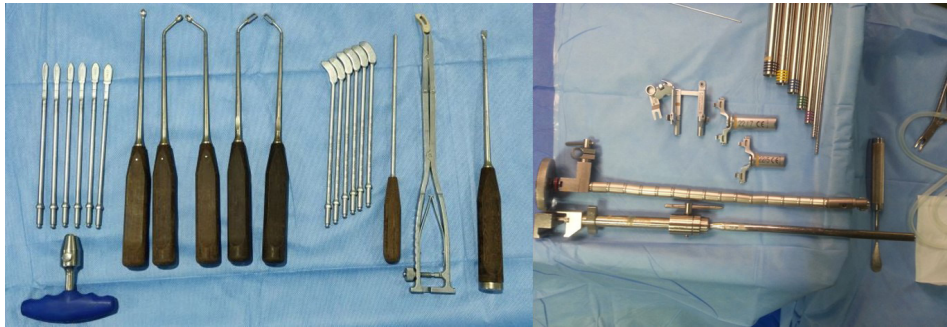#### 4.2.4. End plate preparation and discectomy

The working area of discectomy is the Kambin triangle, bounded by traversing root medially, exiting root super-laterally, and superior facet infero-laterally. Cutting the poster-lateral annulus is the 1st step followed by the gradual removal of the nuclear portion of the disc material with the use of Kerrison Rongeurs, pituitary forceps, or discectomy forceps (Figure 11). The more lateral the



**Figure 11** | Microscopic demonstration of Kambin's triangle and annulotomy of disc.

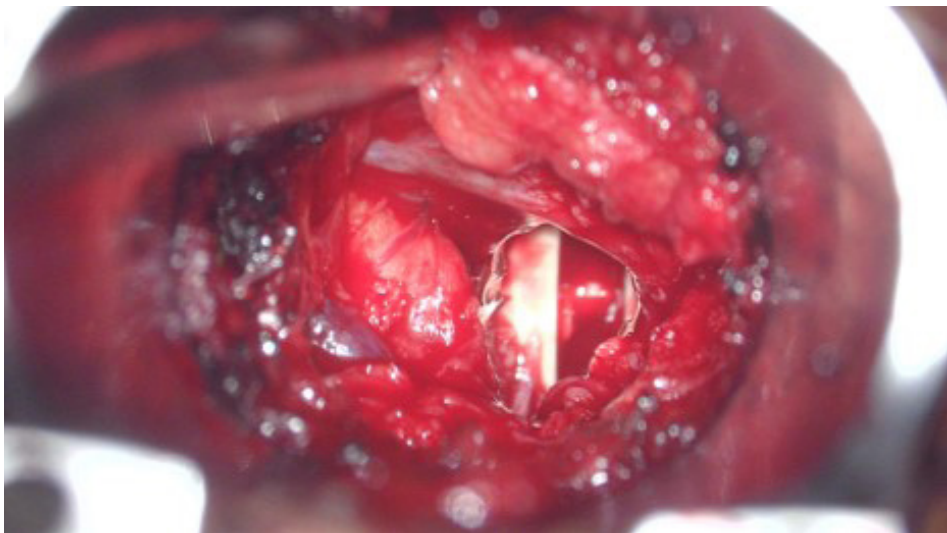
window creation, the more efficient access to the contralateral disc and less neural structure retraction. Excessive handling and vigorous retraction of neural structures causes significant post-operative neuropathic pain. End plates are prepared with paddle distractors, reamers and angled curettes (Figure 12). The typical end plate well prepared gives the characteristic gritty sound with a characteristic feel to the surgeon. End plate preparation is more important in MISS TLIF as compared to open procedure because of the sparsity of graft material.



**Figure 12** | Instrumentation required for interbody workup including MIS tubes.

#### 4.2.5. Cage/graft placement

The prepared disc space is thoroughly washed to remove the loose fragments. Graft material obtained from medial facetectomy is tightly packed in the anterior one-third disc space. Sequential cage sizers are used as trials before placing the final cage. Bean-shaped or banana-shaped PEEK material (Polyethyl Ether Ketone) with filled autografts is preferred at our center. Before placing the cage, distraction using contralateral pedicle screws to open up the disc space to accommodate the larger size cage is done. While placing the cage, the traversing root is retracted and the cage is gently slipped into the space followed by malleting to achieve its placement in the anterior to middle one-third space away from the pedicle screws (Figure 13).

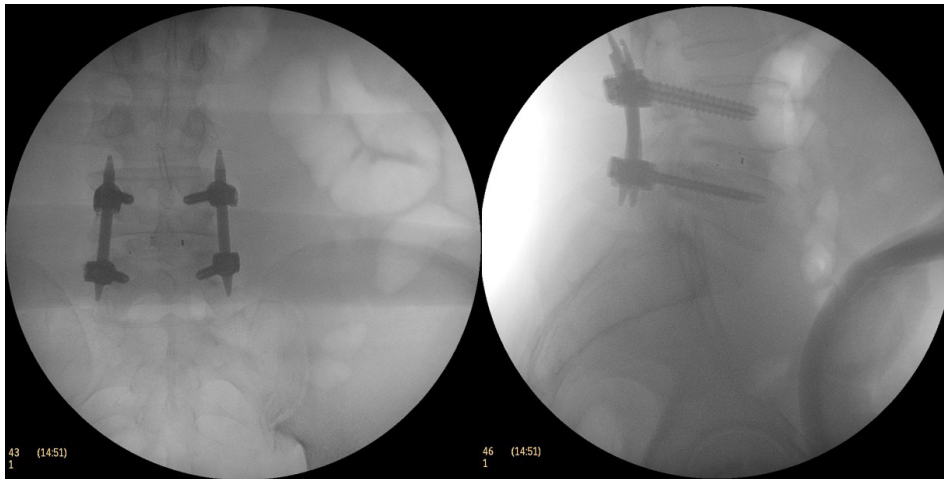


**Figure 13** | Microscopic picture demonstrating the final position of the transforaminal lumbar interbody fusion cage.

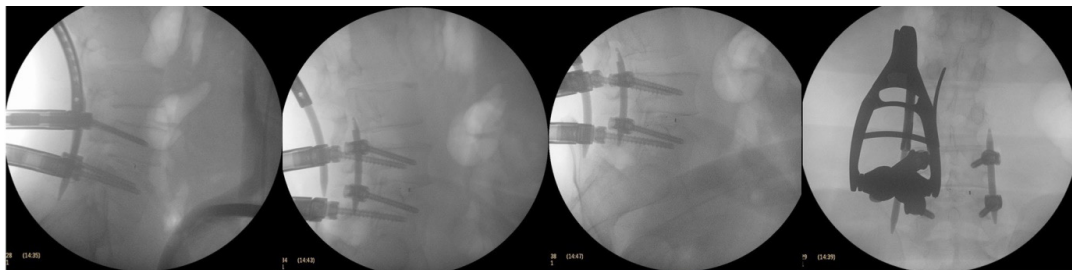


## Minimally invasive spine surgery for lumbar fusion 54

The cage position is confirmed and distraction is released. Ipsilateral pedicle screws are applied in a similar fashion and compression is applied on both sides with fluoroscopic images taken (Figure 14). During rod insertion, palpable engagement is tested by a rod tester and confirmed by radiographs – AP, lateral and oblique, as one-level imaging might be deceptive at times (Figure 15).



**Figure 14** | Fluoroscropy image showing final implant position.



**Figure 15** | AP, lateral and oblique fluoroscropy images to confirm correct rod placement.

### Navigation-guided TLIF:

- Navigation is a reinforcement of anatomy to avoid human error.
- Freehand navigation and robotic assisted navigation

### Intra op adjuncts in Navigation MISS TLIF:

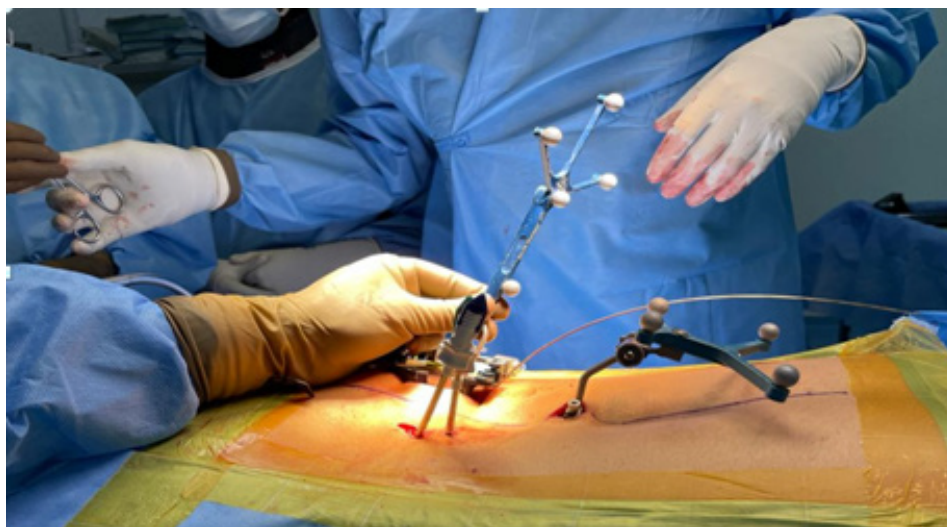
- (a) Pre-op op CT based (first generation)
- (b) Intra op fluoroscropy 2D/3D (second generation)
- (c) Intra op CT – O Arm (third generation)

Workflow for navigation-guided MISS TLIF (Table 1):

**Table 1** | Comparison of various intra op adjuvants (15).

Factors	2D Navigation	Cone beam CT	O-arm
Registration duration	Short	Short	Ultra-short
Image display	2D (AP & Lateral)	3D (axial images)	3D (axial images)
No. of vertebra covered in a single scan	3–5 segments	6–8 segments	Whole spine
Bone image quality	Poor	Good	Good
MISS (minimally invasive spine surgery)	Requires more caution	More accurate	Maximum accurate
Radiation exposure (Patient OR personnel)	Less	More	Maximum

- Placement of reference frame/ percutaneous pin (Figure 16)

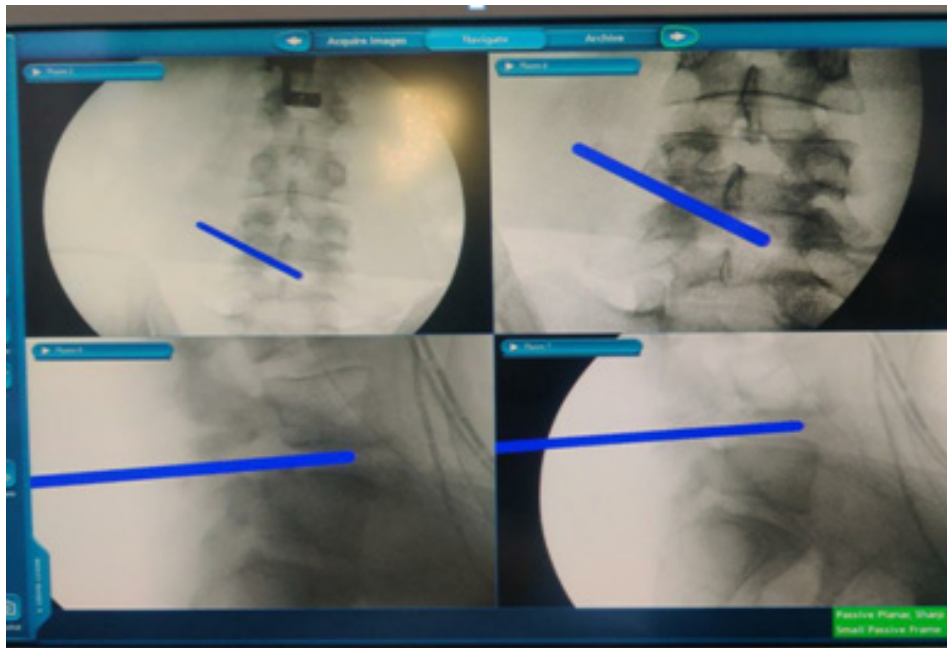

**Figure 16** | Placement of navigation reference frame and percutaneous pins.

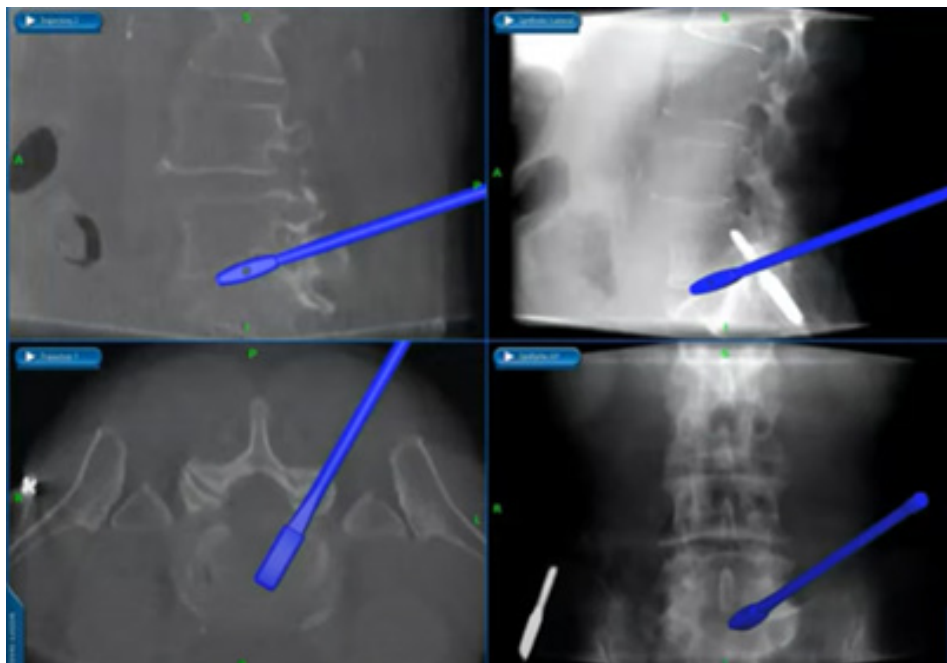
- Acquiring intra-op imaging (fluoroscopy/CT scan)
- Verifying instruments/ accuracy of images with anatomical landmarks (Figure 17)
- The rest of the steps follow the same as MISS-TLIF (Figures 18, 19).

Advantages of navigation-guided TLIF over MISS TLIF:

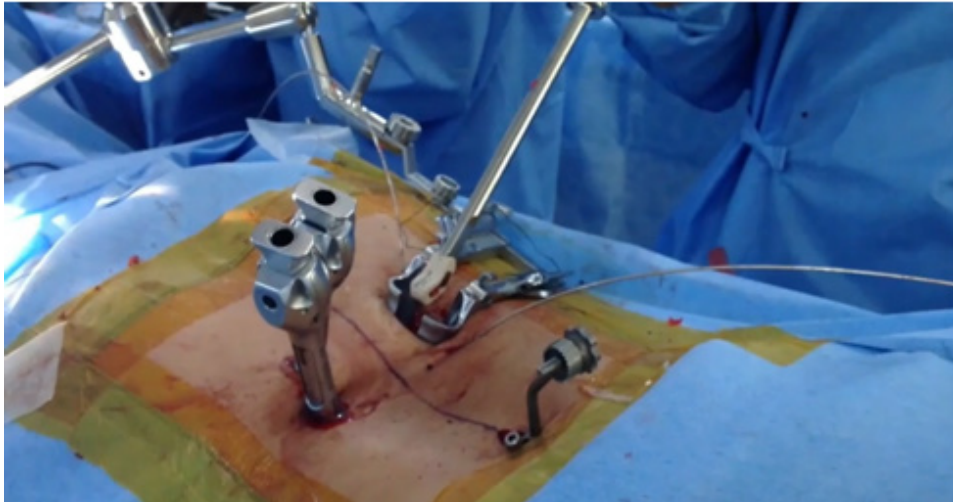
- More accurate localization of pedicle and placement of precise screws



**Figure 17** | Navigation used to localize anatomical landmarks.



**Figure 18** | Use of cage trial with navigation.



**Figure 19** | Navigation aided cage placement.

- Lesser time consumption
- Significantly less radiation exposure
- Teaching tool
- The trend of the future.

Caution factors while using navigation

- Alteration of table height or patient movement
- Image mismatch after surface drilling or dissection
- Obese patients
- Change in the reference after insertion of the cage

### **4.3. Complication and prevention (Table 2)**

With a systematic approach, intra-operative adjuncts, and caution while performing the core steps of MISS TLIF, the occurrence of unwanted and outward events is very less. However, on occasions, even with expertise, some of the complications can manifest.

The table discusses the probability of the occurrence of complications as well as their due management.

### **4.4. Literature review**

In conventional open procedures, iatrogenic muscle damage especially multifidus leads to poor operative outcome measures. These

Table 2 | Complications and its management in MISS TLIF.

Complication	Incidence (%)	Occurrence	Avoidance and management
Dural tears (16)	1.8–13.9	Obese patients and revision surgery. Mostly during cage placement/neural decompression	Small dural tears- need not be sutured. Large dural tears- convert to open procedure and repair.
Screw malalignment (17, 18)	Screw accuracy Fluoroscopy 2D navigation: 69-94%. 3D CT-Navigation 89–98%	Medially oriented facets. Improper visualization of the entry point. Inferior breach-nerve root injury. Medial breach-neural injury	Good intraoperative Co-Axial X-ray imaging. Use of Neuro-Navigation. Constant vigilance for medial breach intra-op.
Nerve root injuries (19)	3.2%	Traversing root injury- during neural decompression. Exiting root injury- during cage placement.	Watch out for low-lying roots. Securing the exiting root with a cotton pellet.
Cage migration (20)	1.2%	More common with small rectangular cage placement secondary to insufficient space creation. More in patients with flat end plates rather than concave end plates.	Osteotomizing the Superior aspect of the lateral facet to create sufficient space and contralateral rod distraction. Posterior migration needs open revision.
Radiation hazard (21)	Fluoroscopy assisted- 2.93 Gy/cm <sup>2</sup> Navigation – 0.47 Gy/cm <sup>2</sup>	Maximum radiation exposure, especially with beginners.	Use of navigation to reduce exposure



instances of muscle damage are demonstrated by an increase in creatine phosphate kinase levels, and post-operative MRI changes (22). MIS-TLIF significantly avoids damage as it is through the anatomical planes. Placement of the pedicle screws via the MIS approach is associated with less blood loss, lesser muscle damage, lesser post-operative pain, lesser use of narcotics, early mobilization, and shortened hospital stay (23). The average duration of MIS-TLIF surgery ranges from 120 mins for a single level to 360 mins for multiple levels and is comparable to 142–312 mins in an open procedure (24, 25).

The average blood loss is significantly lower in MIS - TLIF group (226 ml) as against the open (1147 ml) group (26). The surgical site infections are less compared to open procedures owing to less tissue damage in MIS - TLIF. In recent years, advancements in surgical expertise and instrumentation have led to comparable fusion rates between MIS-TLIF (93.4%) and open procedures (93.8%) (27). The placement of percutaneous pedicle screws is safe and the misplacement rates are comparable to those in the case of open TLIF. Smith et al. (28) demonstrated 6.2% pedicle breaches in a CT-based study of 601 patients and 2/37 breaches were symptomatic.

Huang et al. (29) noted in their systematic review of 12 studies that MIS-TLIF in elderly patients results in a high rate of fusion and significant improvement of patient-reported outcomes but noticed higher complication rates than in non-elderly patients, especially in the multi-level compared to single-level MIS TLIF.

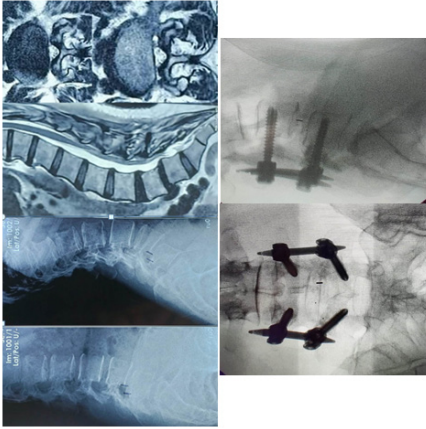
Shuman et al. (30) concluded that surgeons in their learning curve have become faster at the MIS-TLIF procedure. Clinical outcomes, including post-operative pain and fusion rates, showed satisfactory results, but surgeons learning the procedure should take measures to minimize complications in early cases, such as utilizing novel navigation technology or supervision from more experienced surgeons. Arif et al. (31) analyzed 15 studies and concluded that navigation significantly reduced radiation exposure and reduced the surgical time in MIS TLIF.

#### **4.5. Special scenarios (Table 3)**

High-grade listhesis and osteoporosis are relative contraindications, and apart from these, hypertrophic facets and collapsed disc space are indeed challenging cases when it comes to MISS TLIF. The table below discusses the challenges as well as methods to overcome them during MISS TLIF.

**Table 3** | Special scenarios, challenges and pearls to encounter them.

Challenges	Reason	Tips and tricks
Hypertrophied facets (Figure 20)		

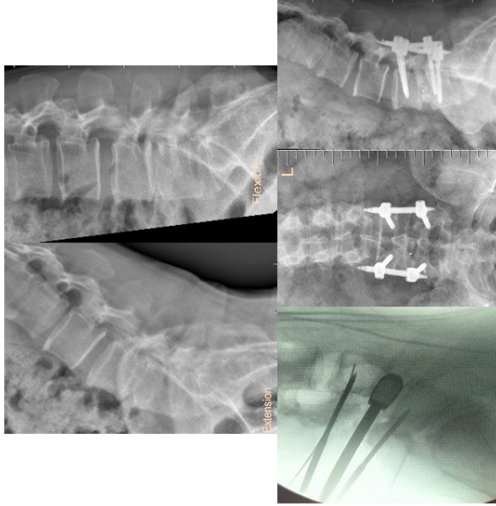


**Figure 20** | Hypertrophied facets- X-ray and MRI, Intra-op imaging post-transforaminal lumbar interbody fusion.

- |                   |  |   |
|-------------------|--|---|
| (a) Docking       | <ul style="list-style-type: none"><li>• Larger facets encroach on the spinous process and covering the pars.</li></ul>   | (a) Rocking movement of the tube, from medial to lateral to sweep the muscles away and dealing with remaining tissues with the use of cautery.<br>Use of liberal fascial incision, expandable tubes and deeper repositioning of the tube after facetectomy. |
| (b) Decompression | <ul style="list-style-type: none"><li>• Ipsilateral – because pars are overlapped by facets</li><li>• Contralateral- owing to huge facets covering spino-laminar junction.</li></ul> | (b) Ipsilateral-Osteotomy after pars and facet identification.<br>Contra-lateral–Burring base of the spinous process, preserving a layer of flavum over dura, and use of high-speed burr to remove contralateral medial facet.                              |

(c) Instrumentation	<ul style="list-style-type: none"><li>• Screw entry is difficult owing to facets covering the starting point.</li><li>• Rod placement is cumbersome.</li><li>• Reduction is difficult- owing to the ankylosed contralateral joint.</li></ul>	Use of Navigation for screw placement, placement of ipsilateral screw post-facetectomy and use of serial tapping.
---------------------	--	---

Collapsed disc space (Figure 21)



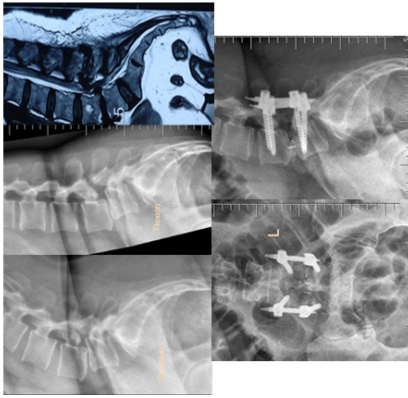
(d) Decompression	(a) In the case of Spondylolysis, which is commonly associated with reduced disc space, exiting root pathology is the cause of pain and difficulty to decompress the contra-lateral exiting nerve root.	(a) Bilateral tube docking especially to decompress the contralateral exiting root in case of spondylolysis.
-------------------	---	--

(Continued)



Challenges	Reason	Tips and tricks
(e) Height restoration	Transforaminal lumbar interbody fusion relies on indirect decompression (Increasing foraminal height), difficult to restore height in collapsed disc space.	(b) Use of osteotome to jack and open up the disc space. Bilateral facetectomy from both sides and increasing disc height from both sides.
(f) Graft availability	(b) Collapsed disc space is usually secondary to degenerated disc disease and less with facet hypertrophy, so less facet growth, and less graft availability.	Use of iliac graft / Grafton (Demineralized bone matrix).

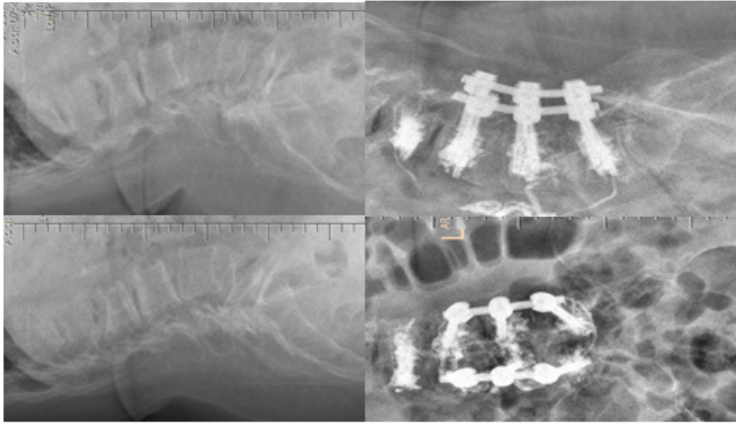
High-grade listhesis (Figure 22): >50% listhesis is a relative contraindication



**Figure 22** | X-ray, MRI showing high-grade listhesis, reduction post-transforaminal lumbar interbody fusion.

(g) Dysplastic pedicles	Lytic listhesis	(a) Larger diameter screws, Bicortical Screws for S1.
(h) Reduction difficulty	Kyphotic angulation of L5 over S1 Inadequate disc release	(b) Larger cage for reduction (c) Sacral osteotomy (d) Complete discectomy from both sides.

Osteoporosis (Figure 23): Severe osteopenia is a relative contraindication for MISS TLIF.



**Figure 23** | X-ray of osteoporotic bones, use of cement-augmented screws.

(i) Screw hold	The screw grip in weak bone increases the chances of pull out	Use of fenestrated screws with cement augmentation.
Interbody fusion	Endplate damage by shavers. Cage migration across endplates into the vertebral body	Careful use of shavers, avoid using cages, and use allografts to augment fusion.

For any instrumentation in osteoporotic bone:

- Thorough patient counseling regarding prognosis.
- Pre-op DEXA scans, as a baseline for documentation.
- Injection of Teriparatide/Denosumab in the post-operative and even pre-operative periods if possible.
- Use of lots of Bone graft- Allograft is a viable option.

## References

1. de Kunder SL, van Kuijk S, Rijkers K, Caelers I, van Hemert W, de Bie R, et al. Transforaminal lumbar interbody fusion (TLIF) versus posterior lumbar interbody fusion (PLIF) in lumbar spondylolisthesis: a systematic review and meta-analysis. *Spine J.* (2017) 17:1712–21.
2. Lan T, Hu SY, Zhang YC, Zhang R, Shen Z, Yang XJ. Comparison between posterior lumbar interbody fusion and transforaminal lumbar interbody fusion for the treatment of lumbar degenerative diseases: a Systematic Review and Meta-Analysis. *World Neurosurg.* (2018) 112:86–93.
3. Cloward RB. The treatment of ruptured lumbar intervertebral discs by vertebral body fusion. I. Indications, operative technique, aftercare. *J Neurosurg.* (1953) 10:154–68.
4. Harms J, Rolinger H. A one-stager procedure in operative treatment of spondylolistheses: dorsal traction-reposition and anterior fusion (author's transl). *Z Orthop Ihre Grenzgeb.* (1982) 120:343–7.
5. Sihvonen T, Hernö A, Paljärvi L, Airaksinen O, Partanen J, Tapaninaho A. Local denervation atrophy of paraspinal muscles in postoperative failed back syndrome. *Spine.* (1993) 18:575–81.
6. Tormenti MJ, Maserati M, Bonfield C, Gerszten P, Moossy J, Kanter A, et al. Perioperative surgical complications of transforaminal lumbar interbody fusion: a single-center experience. *J Neurosurg Spine.* (2012) 16:44–50.
7. Boni L, Benevento A, Cantore F, Dionigi G, Rovera F, Dionigi R. Technological advances in minimally invasive surgery. *Expert Rev Med Devices.* (2006) 3:147–53.
8. Fan S, Zhao X, Zhao F, Fang X. Minimally invasive transforaminal lumbar interbody fusion for the treatment of degenerative lumbar diseases. *Spine.* (2010) 35:1615–20.
9. Cheng JS, Park P, Le H, Reisner L, Chou D, Mummaneni P. Short-term and long-term outcomes of minimally invasive and open transforaminal lumbar interbody fusions: is there a difference? *Neurosurg Focus.* (2013) 35:E6.
10. Serban D, Calina N, Tender G. Standard versus minimally invasive transforaminal lumbar interbody fusion: a prospective randomized study. *Biomed Res Int.* (2017) 2017:7236970.
11. Wong AP, Smith Z, Stadler J III, Hu X, Yan J, Li X, et al. Minimally invasive transforaminal lumbar interbody fusion (MI-TLIF): surgical technique, long-term 4-year prospective outcomes, and complications compared with an open TLIF cohort. *Neurosurg Clin N Am.* (2014) 25:279–304.

12. Xie Q, Zhang J, Lu F, Wu H, Chen Z, Jian F. Minimally invasive versus open transforaminal lumbar interbody fusion in obese patients: a meta-analysis. *BMC Musculoskelet Disord.* (2018) 19:15. doi: 10.1186/s12891-018-1937-6
13. Adogwa O, Carr K, Thompson P, Hoang K, Darlington T, Perez E, et al. A prospective, multi-institutional comparative effectiveness study of lumbar spine surgery in morbidly obese patients: does minimally invasive transforaminal lumbar interbody fusion result in superior outcomes? *World Neurosurg.* (2015) 83:860–6.
14. Kim JE, Yoo HS, Choi DJ, Park EJ, Jee SM. Comparison of minimal invasive versus biportal endoscopic transforaminal lumbar interbody fusion for single-level lumbar disease. *Clin Spine Surg.* (2021) 34:E64–71.
15. Vaccaro AR. *The spine medical & surgical conditions.*
16. Klingler JH, Volz F, Krüger M, Kogias E, Rölz R, Scholz C, et al. Accidental durotomy in minimally invasive transforaminal lumbar interbody fusion: frequency, risk factors, and management. *Sci World J.* (2015) 2015:532628.
17. Torres J, James A, Alimi M, Tsiouris A, Geannette C, Härtl R. Screw placement accuracy for minimally invasive transforaminal lumbar interbody fusion surgery: a study on 3-d neuronavigation-guided surgery. *Global Spine J.* (2012) 2:143–51.
18. Wang J, Zhou Y. Perioperative complications related to minimally invasive transforaminal lumbar fusion: evaluation of 204 operations on lumbar instability at single center. *Spine J.* (2014) 14:2078–84.
19. Joseph JR, Smith BW, la Marca F, Park P. Comparison of complication rates of minimally invasive transforaminal lumbar interbody fusion and lateral lumbar interbody fusion: a systematic review of the literature. *Neurosurg Focus.* (2015) 39:E4.
20. Zhao FD, Yang W, Shan Z, Wang J, Chen H, Hong Z, et al. Cage migration after transforaminal lumbar interbody fusion and factors related to it. *Orthop Surg.* (2012) 4:227–32.
21. Dusad T, Kundnani V, Dutta S, Patel A, Mehta G, Singh M. Comparative prospective study reporting intraoperative parameters, pedicle screw perforation, and radiation exposure in navigation-guided versus non-navigated fluoroscopy-assisted minimal invasive transforaminal lumbar interbody fusion. *Asian Spine J.* (2018) 12:309–16.
22. Lombao D, Bagó J, Vilor T. Validity of creatine kinase as an indicator of muscle injury in spine surgery and its relation with postoperative pain. *Acta Orthop Belg.* (2014) 80:545–50.
23. Patel DV, Bawa M, Haws B, Khechen B, Block A, Karmarkar S, et al. PROMIS Physical Function for prediction of postoperative pain, narcotics consumption, and patient-reported outcomes following minimally invasive transforaminal lumbar interbody fusion. *J Neurosurg Spine.* (2019) 30:476–82.
24. Wang J, Zhou Y, Zhang ZF, Li CQ, Zheng WJ, Liu J. Comparison of one-level minimally invasive and open transforaminal lumbar interbody fusion in degenerative and isthmic spondylolisthesis grades 1 and 2. *Eur Spine J.* (2010) 19:1780–4.
25. Isaacs RE, Podichetty V, Santiago P, Sandhu F, Spears J, Kelly K, et al. Minimally invasive microendoscopy-assisted transforaminal lumbar interbody fusion with instrumentation. *J Neurosurg Spine.* (2005) 3:98–105.
26. Goldstein CL, Macwan K, Sundararajan K, Rampersaud YR. Perioperative outcomes and adverse events of minimally invasive versus open posterior lumbar fusion: meta-analysis and systematic review. *J Neurosurg Spine.* (2016) 24:416–27.

## Minimally invasive spine surgery for lumbar fusion 66

27. Kim MC, Chung HT, Kim DJ, Kim SH, Jeon SH. The clinical and radiological outcomes of minimally invasive transforaminal lumbar interbody single level fusion. *Asian Spine J.* (2011) 5:111–6.
28. Smith ZA, Sugimoto K, Lawton CD, Fessler RG. Incidence of lumbar spine pedicle breach after percutaneous screw fixation: a radiographic evaluation of 601 screws in 151 patients. *J Spinal Disord Tech.* (2014) 27:358–63.
29. Huang J, Rabin EE, Stricsek GP, Swong KN. Outcomes and complications of minimally invasive transforaminal lumbar interbody fusion in the elderly: a systematic review and meta-analysis. *J Neurosurg Spine.* (2021) 36:741–52.
30. Shuman WH, Baron R, Neifert S, Martini M, Chapman E, Schupper A, et al. MIS-TLIF procedure is improving with experience: systematic review of the learning curve over the last decade. *Clin Spine Surg.* (2022) 35:376–82.
31. Arif S, Brady Z, Enchev Y, Peev N, Encheva E. Minimising radiation exposure to the surgeon in minimally invasive spine surgeries: a systematic review of 15 studies. *Orthop Traumatol Surg Res.* (2021) 107:102795.

# Percutaneous pedicle screw fixation-Techniques and complication avoidance

---

**Chandan B. Mohanty**

Bai Jerbai Wadia Hospital for Children,  
Bombay Hospital Institute of Medical Sciences, Mumbai, India

1. Introduction .....	67
2. Indications (1–4) .....	68
3. Rationale of PPSI .....	68
4. Technique of PPSI.....	69
4.1. The surgical steps are as follows (1, 2):.....	69
5. Challenges in PPSI.....	75
5.1. Small, sclerotic pedicles.....	75
5.2. Changing screw trajectory.....	75
5.3. Close proximity of certain screws especially of L5 S1 .....	76
5.4. K wire related.....	76
5.5. Multi-level fixation.....	78
6. Complications and limitations of PPSI .....	78
7. Conclusion.....	79
References .....	79

## 1. Introduction

Pedicle screws provide a robust method to achieve three-column spinal stability and have stood the test of time. The widespread use of MISS techniques and the growing indications for MISS have meant that the use of percutaneous pedicle screw instrumentation

(PPSI) is also growing and is an important tool in the armamentarium of a minimally invasive spine surgeon (1, 2). As with any technique, there is a learning curve associated with this technique. In this paper, we shall discuss the techniques, nuances, and complications of PPSI and tips to avoid the complications.

## **2. Indications (1–4)**

- (1) Thoracolumbar spinal fractures (A2, A3, A4, B1, and B2 injuries).
- (2) Spinal infections like Tuberculous or pyogenic osteomyelitis.
- (3) Spondylolisthesis Degenerative and Isthmic.
- (4) Spinal tumors causing instability.
- (5) Recurrent disc herniation.
- (6) Spinal deformity.
- (7) Osteoporotic spinal fractures.

Percutaneous pedicle screw instrumentation is usually performed as a standalone procedure in selected cases of trauma and spinal deformity but is usually performed as an additional adjunct procedure like transforaminal lumbar interbody fusion (TLIF), vertebroplasty, decompression of spinal canal, etc. if required (3–5). The relative contraindication of this procedure includes non-visualization of pedicles on fluoroscopy in morbidly obese patients, patients with high-grade spondylolisthesis, and severe kyphoscoliotic deformity of the spine (2). Patients with very small and sclerosed pedicles are also a relative contraindication.

## **3. Rationale of PPSI**

Percutaneous pedicle screw instrumentation involves the placement of screws without detaching the paraspinal muscles, especially the multifidus from its attachment. Multifidus is an extremely important muscle and acts as a dynamic stabilizer of the spine, especially during flexion (6). Preservation of multifidus muscle is thus one of the most important tenets of PPSI compared with open techniques. In addition, PPSI has been associated with decreased blood loss, decreased requirement of post-operative analgesia, shorter hospital stay, and early post-operative ambulation. PPSI also preserves the

posterior midline ligamentous structures like supraspinous and interspinous ligaments.

## **4. Technique of PPSI**

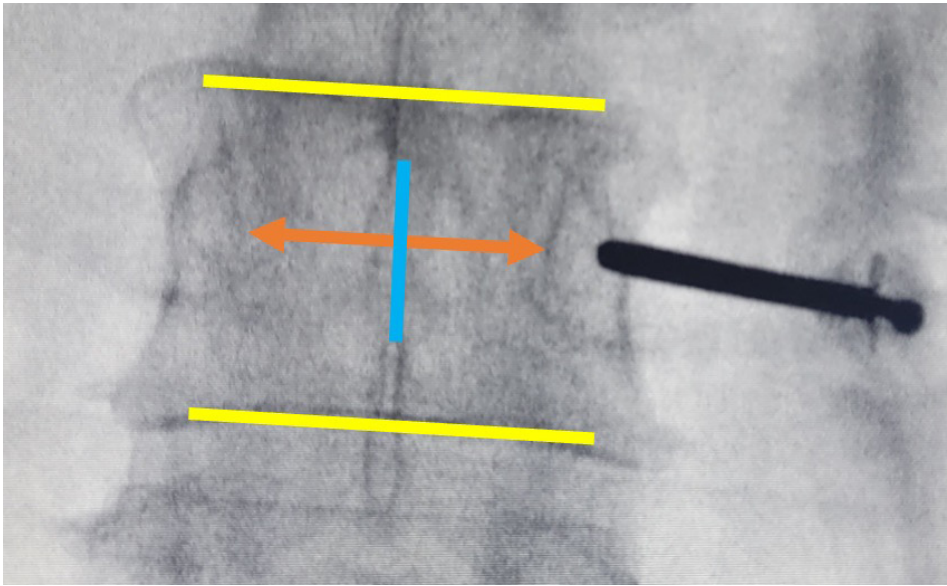
Percutaneous pedicle screw instrumentation comprises two types, namely, navigation guided and non-navigation guided PPSI. Navigation-guided PPSI further comprises fluoro-navigation (Fluoroscopic 2D), preoperative CT based, and Cone-beam CT based (O-arm). Cone-beam CT-based PPSI provides the unique advantage of the placement of screws with navigation guidance in all three planes, namely, axial, sagittal, and coronal, and thus improves the accuracy of screw placement though cost and availability are prohibitive factors. Modern robot-assisted PPSI generally uses either the preoperative CT or an intraoperative cone beam CT for registration, planning, and placement of screws (7). Non-navigation consists of fluoroscopic-guided and free-hand techniques (non-fluoroscopic). The fluoroscopic guides are true AP fluoroscopy and Magerl's technique (Owl's eye technique or pedicle axis view technique). We will mainly discuss the non-navigation fluoroscopic-guided PPSI in the following section.

### **4.1. The surgical steps are as follows (1, 2):**

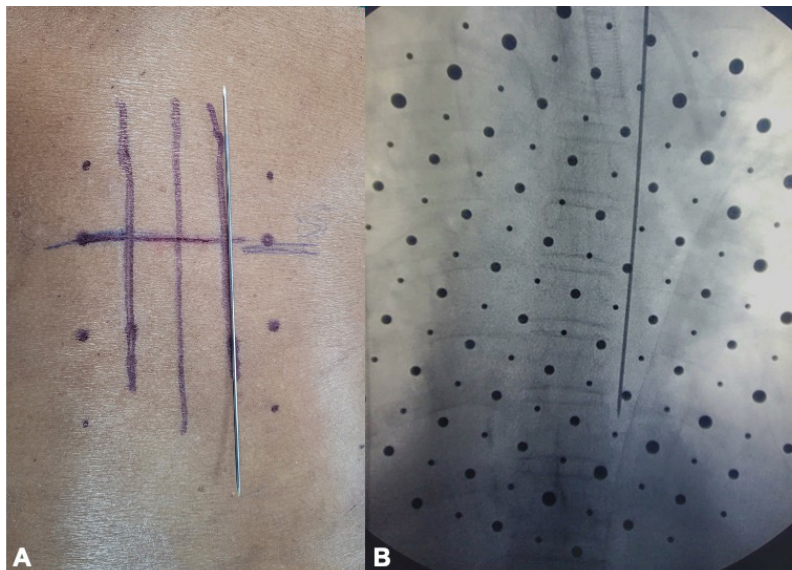
- (1) After anesthesia, the patient is placed prone on bolsters on a radiolucent OT table or a Jackson table. This is important to allow unimpeded access to the fluoroscopy machine to image the patient in multiple planes if necessary.
- (2) Typically, a true AP X-ray of the desired level is obtained. A true AP image typically consists of "squaring" of the upper and lower end plate of the vertebral body, a well-defined oval appearance of the bilateral pedicles, and equidistance of the spinous process from both the pedicles (Figure 1).
- (3) After obtaining the true AP image, a K wire is parallelly placed about 0.5 to 1°cm lateral to the lateral border of the pedicle (Figure 2). Obese patients require a more laterally placed skin incision to achieve optimal medialization of the screw. This denotes the site of the skin incision which is infiltrated with 2% lignocaine.



## Percutaneous pedicle screw fixation–Technique 70



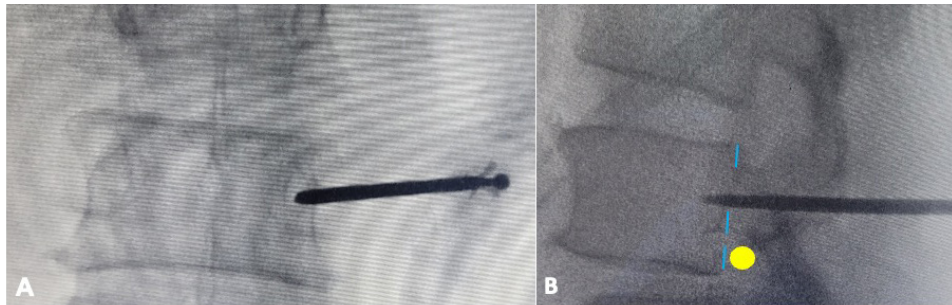
**Figure 1** | True AP X-ray consists of “squaring” of the endplates (yellow lines), equidistance of well-defined oval pedicles from the spinous process (blue line). The Jamshidi needle tip is docked at the 3 O’clock position of the pedicle.



**Figure 2** | (A) A skin incision is marked by using a K wire parallel to midline. This skin incision is based on the AP X-ray where the incision is about 0.5°cm lateral to the lateral edge of the pedicle (B).

- (4) Usually, a 1°cm incision is made and a Jamshidi needle is carefully inserted to dock at the 3 O’ clock position on the right pedicle and 9 O’ clock position on the left side as seen on the AP X-ray (Figure 1).

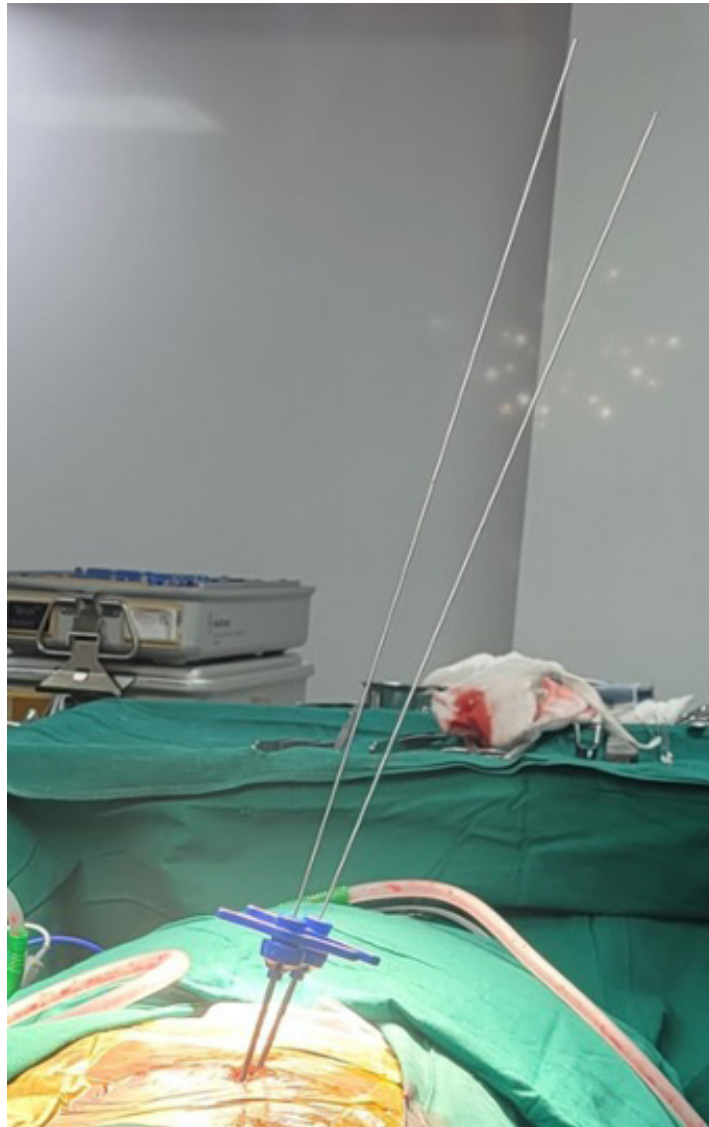
- (5) Following this, the Jamshidi needle is advanced into the pedicle carefully using a cork-screw motion till the 20 mm mark on the Jamshidi needle is reached. Intermittent AP fluoroscopy images may be obtained at this point to make sure the trajectory of the Jamshidi needle is parallel to the superior endplate and does not breach the medial border of the pedicle on the AP image. This ensures that there is no medial breach of the pedicle wall into the spinal canal (Figure 3).



**Figure 3** | (A) AP X-ray showing that the Jamshidi needle tip has reached near the medial border of the pedicle. (B) Lateral X-ray showing that the needle tip has crossed the posterior vertebral cortex (dotted blue lines), thus ensuring that the needle has not violated the spinal canal. Lateral X-ray also shows needle parallel to superior endplate of the vertebra. The inferior wall of the pedicle is not violated, since the exiting nerve root (yellow circle) is in close proximity to the inferior wall of the pedicle.

- (6) Once the needle reaches the medial wall of the pedicle between the 20 and 25 mm mark of the Jamshidi needle, a lateral X-ray is obtained. Again, it is important that the superior and endplate are seen parallel to each other without any parallax effect between them. On lateral X-ray, the needle should have crossed the posterior vertebral body cortex to lie within the vertebral body. This ensures that there is no medial breach of the pedicle (Figure 3).
- (7) The needle is passed further anteriorly up to the junction of the anterior and middle one-third of the vertebral body. The blunt end of the K wire is then passed through the Jamshidi needle (Figure 4) and then the Jamshidi needle is carefully removed.
- (8) An appropriately sized tap is then used over the K wire. After the tap is removed, an appropriately sized fenestrated screw as measured on preoperative imaging is passed over the K wire with intermittent fluoroscopic images to confirm the screw

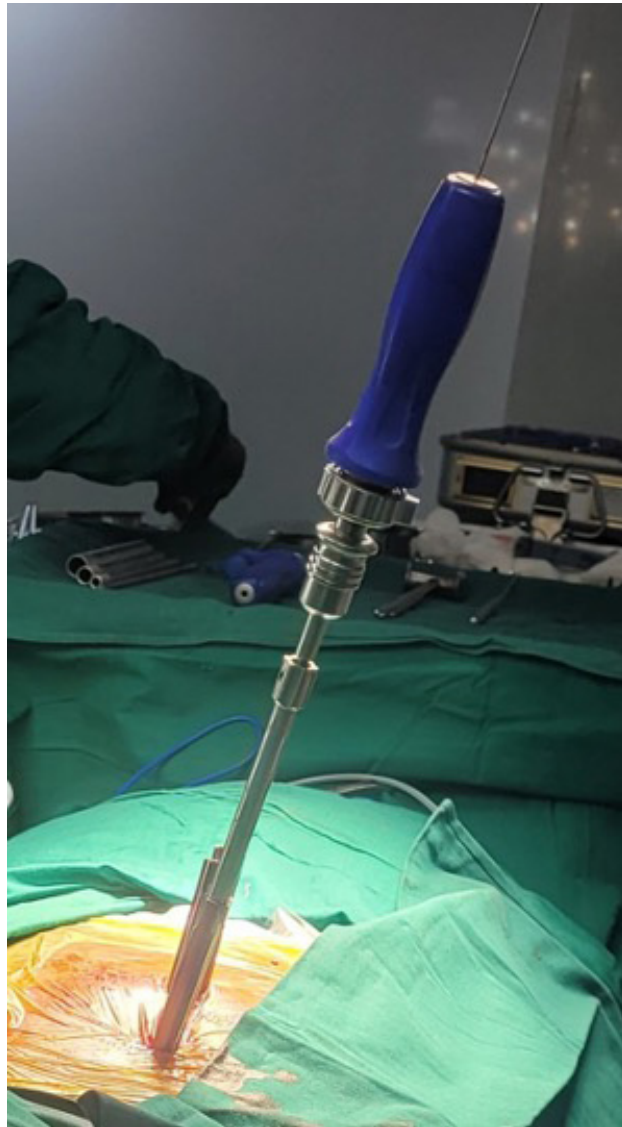
## Percutaneous pedicle screw fixation–Technique 72



**Figure 4** | Clinical picture showing placement of K wire after removal of the stylet of the Jamshidi needle.

trajectory (Figure 5). The screw with its extension tab (also called retraction sleeve or screw tower) is left in place.

- (9) The K wire is then removed and the same process of screw placement is performed at other levels.
- (10) An appropriately sized rod is then cut and bent and is then placed over the screw heads with the tab. Most of the PPSI systems allow rod insertion over the screw tab through the same incision while other systems require a separate stab incision for



**Figure 5** | Clinical picture showing placement of appropriately sized pedicle screw passed over the K wire.

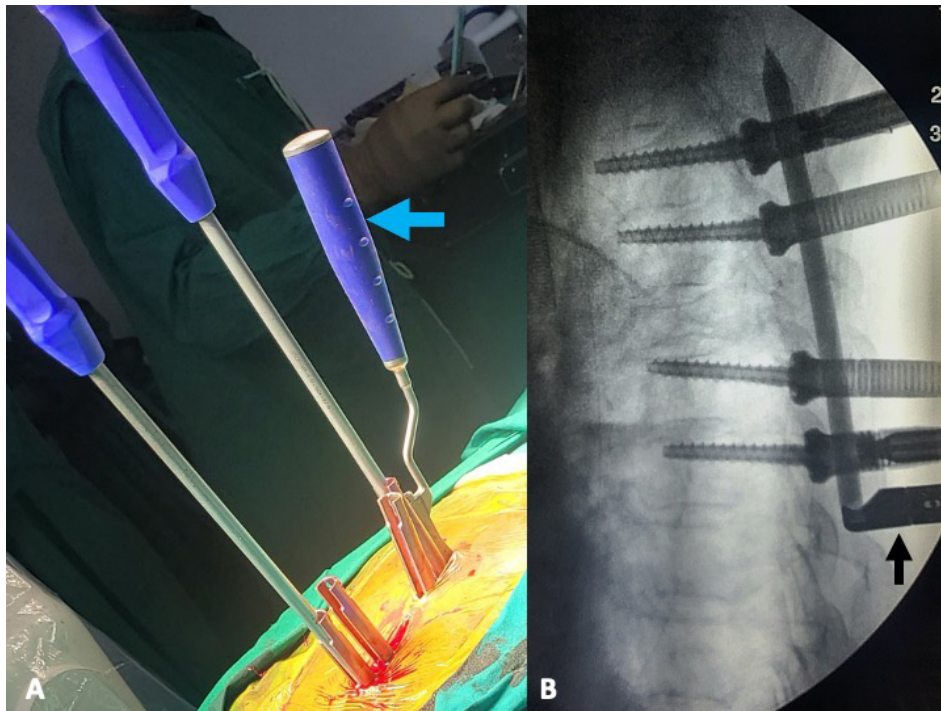
placement of the rod into the screw tabs through the subfascial plane (Figure 6).

- (11) Top-loading set screws are then tightened to secure the rods over the pedicle screws and the screw tabs are broken from the pedicle screws.

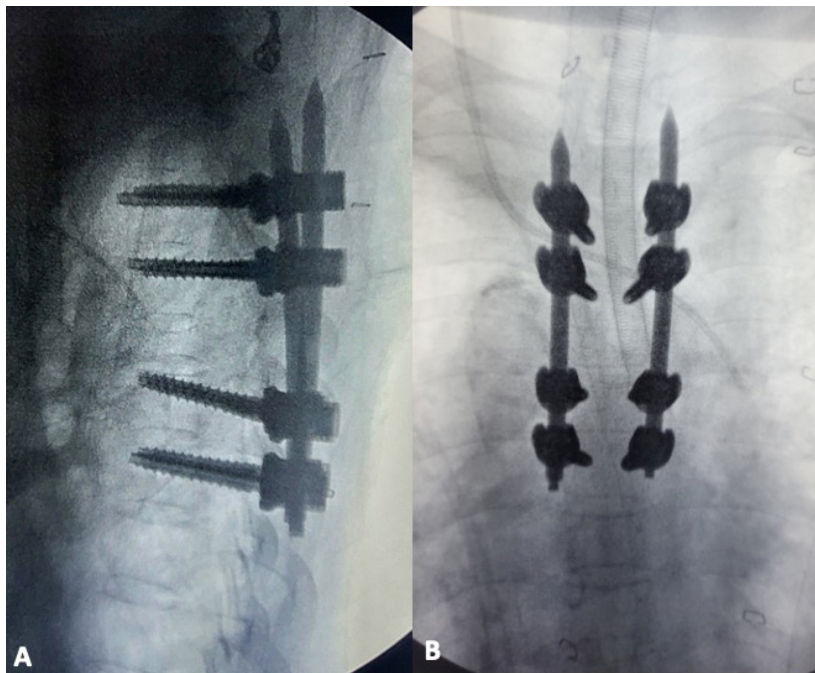
AP and lateral X-rays are taken throughout these steps to ensure satisfactory screw and rod position (Figure 7).



## Percutaneous pedicle screw fixation–Technique 74



**Figure 6** | Patient with T5 body collapse secondary to tuberculosis. (A) Clinical photograph showing rod holder (blue arrow) passed along the screw extension tab. (B) Lateral X-ray showing that the rod has been successfully passed subfascially to engage all the screw heads. Black arrow shows the rod holder.



**Figure 7** | (A) Lateral and (B) AP X-ray showing T3-T7 PPSI done in a patient with T5 vertebral collapse secondary to tuberculosis.

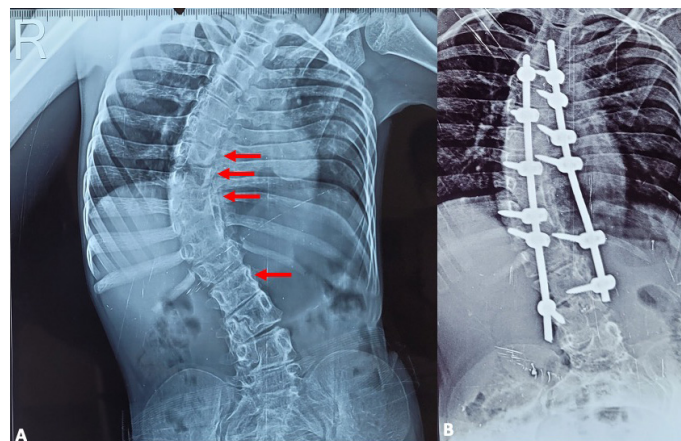
## 5. Challenges in PPSI

### 5.1. Small, sclerotic pedicles

Small pedicles are particularly challenging since the visualization of these pedicles is difficult in the fluoroscopic image. In this case, navigation-based PPSI is particularly useful. In the absence of navigation, it is possible to visualize the pedicle through the pedicle axis view (oblique view), where we get an “end-on” view of the pedicle for ease of placement of pedicle screws. The author prefers to measure the width of the pedicle preoperatively to anticipate and prepare for any intraoperative difficulty. Sclerotic pedicles can be challenging to cannulate with a Jamshidi needle. A slightly longer incision is preferred by the author and the pedicle screw can be placed by a mini-open technique using a pedicle probe or high-speed drill (1). Alternatively, if a multi-level instrumentation is being considered, then the affected level can be skipped altogether and more proximal or distal pedicle screw anchor points can be chosen.

### 5.2. Changing screw trajectory

Changing a screw trajectory is important to achieve ideal screw position. Using an undersized screw tap or the Jamshidi needle over the K wire, the screw trajectory can be changed under fluoroscopic control in the desired direction (1, 2). The wire is then withdrawn and replaced again in the new altered trajectory (Figure 8). However,

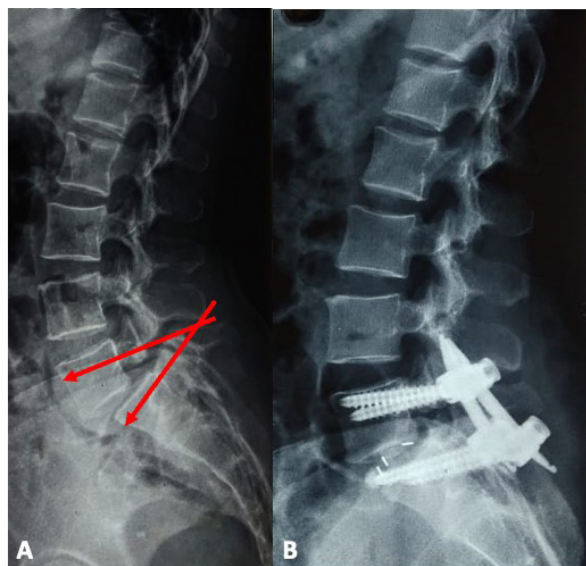


**Figure 8** | (A) Preoperative AP X-ray showing small hypoplastic pedicles (red arrows) at multiple levels on the concave side of the scoliotic deformity. Placement of PPSI is a contraindication in these cases and the patient underwent open pedicle screw fixation and correction of the deformity (B).

it is imperative that extreme change in the trajectory is avoided to avoid bending or breaking the wire.

### 5.3. Close proximity of certain screws especially of L5 S1

Close proximity of pedicle screws at transition of spinal curve especially at L5 and S1 level can be problematic since one screw tab can interfere with placement of the other screw at the level of the skin. This can be overcome by using a more inferior starting point for S1 screw, which allows easy screw placement without impingement of the screw tabs (Figure 9) (1). Certain PPSI systems have a flexible screw retraction sleeve instead of a rigid screw extension tab, which makes it easier to manipulate and avoid impingement (1).



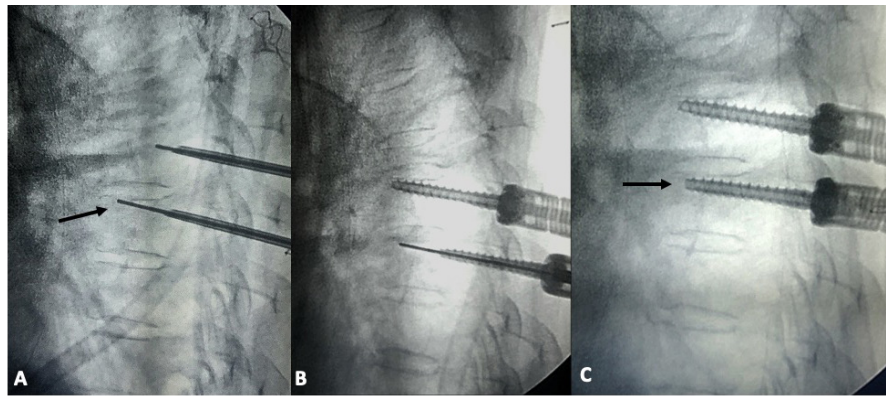
**Figure 9** | (A) Lateral preoperative X-ray showing L5 S1 isthmic spondylolisthesis with red arrows showing the trajectories L5, S1 screw with the extension tabs. (B) Post-operative lateral X-ray showing L5S1 minimally invasive TLIF (MISS-TLIF). The possible screw impingement was avoided by selecting a slightly lower entry point for S1 screw bilaterally.

### 5.4. K wire related

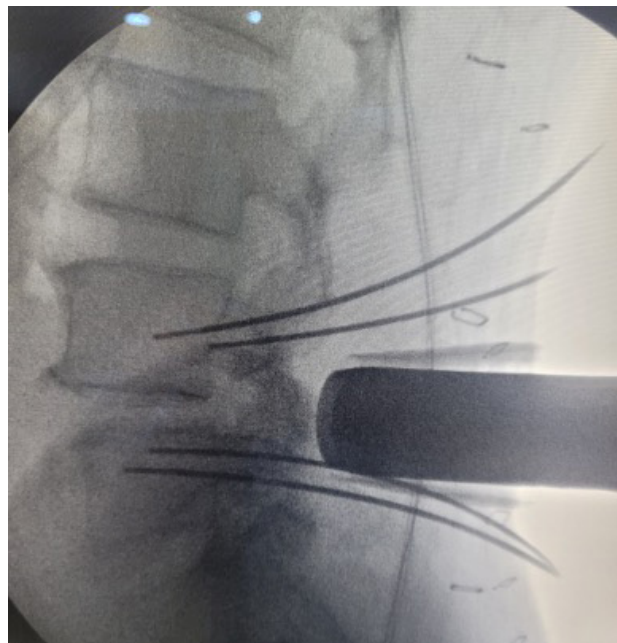K wires should always be handled with care since they are capable of perforating through the bone cortex to cause bowel or vascular injury especially in the presence of osteoporosis. K wires are easily displaced during the course of surgery especially while removing the Jamshidi needle and the tap. This is easily avoidable if the assistant holds the



K wire with an artery forceps to prevent displacement. While placing the screws, it is possible to push the K wires anteriorly through the anterior vertebral cortex of if the direction of the screw does not align with the direction of the K wire. Frequent X-rays with a close eye on the K wire position is critical to prevent mishaps (Figure 11). The author prefers to always use the blunt end of the K wire in the pedicle to avoid perforation. Some of the recent PPSI systems currently use a “wireless” technique where the use of K wire is altogether avoided.



**Figure 10 |** (A) Lateral X-ray showing the K wire abutting the superior endplate (arrow). (B) Lateral X-ray showing screw being passed over K wire with a slight inferior trajectory to avoid violating the superior endplate. (C) Lateral X-ray showing the final screw position (arrow) achieved without violating the superior endplate.



**Figure 11 |** Lateral X-ray showing one of the K wire was displaced outward (arrow) during docking of the tubular retractor to perform a facetectomy for MISS-TLIF. This was identified and the wire was replaced and carefully secured.



### 5.5. Multi-level fixation

Multi-level screw fixation has two unique problems. The first possible problem is planning the skin incision precisely so as to make sure that the skin incision is preferable in a straight line (Figure 1). This helps in rod placement. The second problem with multilevel fixation is to ensure that the screw heads are aligned in such a way that the rod can be passed through all the screws without having to bend the rod in a non-physiological manner. Typically, the rod is first passed from the end where the screw head is closest to the skin surface (1). The rod may be required to be placed through a separate stab incision or through the same incision depending on PPSI system being used.

## 6. Complications and limitations of PPSI

In a large study of 781 patients undergoing PPSI, the total complication rate reported was about 6%. Guide wire breakage was seen in 0.4% patients, screw malposition was noted in 2.1% cases, implant failure 1.8%, wound infection 0.6%, and 1 patient had an abdominal aortic injury (8). Phan et al. in their meta-analysis comparing open pedicle screw fixation with PPSI for thoracolumbar fractures showed significant advantages of PPSI in terms of wound infection (0.3 vs. 3.4%), shorter operative duration, lesser blood loss, shorter hospital stay, lower post-operative VAS scores, and a trend toward lower screw malposition rates (3 vs. 4.2%) (9). Significant kyphotic and scoliotic deformity, severe obesity, and osteoporosis make accurate placement of PPSI difficult in the absence of navigation. In addition, PPSI has a learning curve associated with it and it is important for a surgeon to be well versed in open techniques in cases where PPSI is difficult, especially in the absence of navigation guidance. Familiarity with the anatomy, C-arm, and image interpretation is important for PPSI since the entire surgery needs to be done with fluoroscopic guidance alone. PPSI results in a significantly higher radiation exposure to the patient and the operative team than conventional open pedicle screw fixation (10). Placement of bone graft during PPSI is not as straightforward as with open pedicle screw placement. Current PPSI systems have not yet adequately addressed the problem of implant revision or management of adjacent segment

disease with a minimally invasive approach. A mini-open or open technique is required for management of these cases.

## 7. Conclusion

Percutaneous pedicle screw instrumentation has distinct advantages over open pedicle screw fixation techniques. However, PPSI has its own set of unique challenges. The surgeon should be well versed with indications, technique, nuances, and complications of PPSI to achieve a satisfactory clinical outcome.

## References

1. Mobbs R, Sivabalan P, Li J. Technique, challenges and indications for percutaneous pedicle screw fixation. *J Clin Neurosci.* (2011) 18:741–9.
2. Sardhara J, Deora H. Technique and Pearls of Percutaneous Pedicle Screw Fixation. In: Sardhara J, Mehrotra A, Das KK, Bhaisora KS, Behari S editors. *Minimally Invasive Spine Surgery*. Iaşi: Saubris (2019).
3. Mohanty C. Percutaneous vertebroplasty Technique and review of literature. *J Spinal Surg.* (2022) 9:144–8.
4. Borkar S, Sastri S, Mohanty C, Bansal T. Therapeutic spinal injections and percutaneous procedures An overview. *Curr Pract Neurosci.* (2022) 4:1–24.
5. Lener S, Wipplinger C, Hernandez R, Hussain I, Kirnaz S, Navarro-Ramirez R, et al. Defining the MIS-TLIF: a systematic review of techniques and technologies used by surgeons worldwide. *Global Spine J.* (2020) 10(Suppl. 2):151S–67S.
6. Hildebrandt M, Fankhauser G, Meichtry A, Luomajoki H. Correlation between lumbar dysfunction and fat infiltration in lumbar multifidus muscles in patients with low back pain. *BMC Musculoskelet Disord.* (2017) 18:12. doi: 10.1186/s12891-016-1376-1
7. Lieberman I, Kisinde S, Hesselbacher S. Robotic-assisted pedicle screw placement during spine surgery. *JBJS Essent Surg Tech.* (2020) 10:e0020.
8. Zhao Q, Zhang H, Hao D, Guo H, Wang B, He B. Complications of percutaneous pedicle screw fixation in treating thoracolumbar and lumbar fracture. *Medicine.* (2018) 97:e11560.
9. Phan K, Rao P, Mobbs R. Percutaneous versus open pedicle screw fixation for treatment of thoracolumbar fractures: systematic review and meta-analysis of comparative studies. *Clin Neurol Neurosurg.* (2015) 135:85–92.
10. Kim CH, Lee C-H, Kim KP. How high are radiation-related risks in minimally invasive transforaminal lumbar interbody fusion compared with traditional open surgery? *J Spinal Disord Tech.* (2016) 29:52–9.



# Anterior and lateral minimally invasive approaches to lumbar spine

**Umesh Srikantha, Akshay S. Hari,  
Yadhu K. Loknath and Deepak Somasundaram**

Department of Neurosurgery, Aster CMI Hospital,  
Bengaluru, Karnataka, India

1. Rationale and introduction .....	81
2. Indications .....	84
3. Contra-indications .....	84
4. Technique .....	85
5. OLIF L5-S1 .....	87
6. Clinical outcomes .....	89
7. Summary .....	89
References .....	89

## 1. Rationale and introduction

Lumbar interbody fusion techniques have seen a significant evolutionary growth in the past two to three decades, owing to introduction of minimally invasive techniques as well as a successful resurgence of lateral and anterior approaches. With greater understanding and importance given to sagittal and coronal balance and spino-pelvic parameters in fusion surgeries, anterior and lateral approaches have shown enormous promise and superiority in maintaining and/or restoring these spinal parameters to achieve an “optimally balanced” spine (1–4). The rationale for anterior and lat-

eral approaches to the lumbar spine is simple. A posterior approach to the spine, even if minimally invasive, involves certain amount of injury to the posterior tension band and paraspinal muscles in addition to all of them being intra-canal approaches, with risk of injury to the dura/nerve root and post-operative epidural adhesions with its consequent clinical symptoms. This is completely avoided in anterior and lateral approaches (Table 1). Since the spinal canal

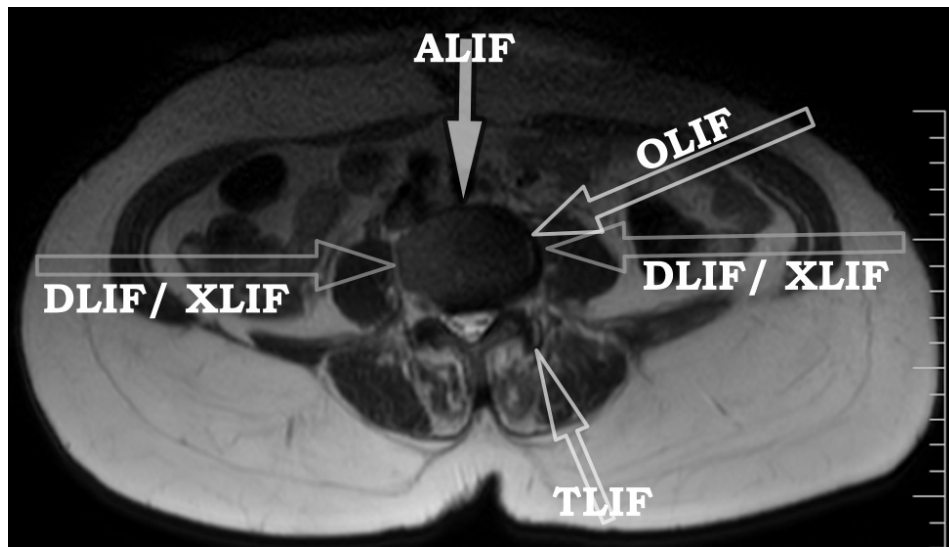
**Table 1** | Comparative difference between a conventional (open) TLIF, MIS-TLIF and the lateral/anterior approaches.

Open TLIF	MIS-TLIF	OLIF/ALIF
Significant injury to paraspinal muscles	Less injury to paraspinal muscles	Paraspinal muscles completely untouched
Risk of epidural adhesions and post-operative radiculitis/dysesthesias	Risk of epidural adhesions and post-operative radiculitis/dysesthesias	Nerves not touched—no risk of epidural scarring and consequent symptoms
Risk of direct injury to nerve/dural sac	Risk of direct injury to nerve/dural sac	No risk
One side/both sides facet joints removed	One side/both sides facet joints removed	Complete preservation of both facet joints
Some spine ligaments removed/injured	Relatively less injury to ligaments	Complete preservation of all spinal ligaments (Exc. ALL in ALIF)
Relatively small cage	Relatively small cage	Large cage. Better stability in weak bones

ALL, anterior longitudinal ligament; TLIF, transforaminal lumbar interbody fusion; MIS TLIF, minimally invasive TLIF; OLIF, oblique lumbar interbody fusion; ALIF, anterior lumbar interbody fusion.

is not traversed and the posterior elements are left intact, the risk of any intra-canal approach related complication is completely avoided in the anterior and lateral approaches (5, 6). The following are the minimally invasive anterior or lateral approaches to the lumbar spine (Figure 1):

1. Anterior approach—ALIF (anterior lumbar interbody fusion)—This is usually done with retroperitoneal but can also be done with transperitoneal route.



**Figure 1** | Illustration showing the various anterior and lateral approaches in relation to the standard and commonly performed TLIF approach. ALIF, anterior lumbar interbody fusion; DLIF, direct lateral lumbar interbody fusion; XLIF, extreme lateral lumbar interbody fusion; OLIF, oblique lumbar interbody fusion; TLIF, transforaminal lumbar interbody fusion.

## 2. Lateral approaches

- a. DLIF (direct lateral lumbar interbody fusion) or XLIF (extreme lateral lumbar interbody fusion)—retroperitoneal transpsoas approach to the disc—can be done from right or left side at L2–L5 levels
- b. OLIF (oblique lumbar interbody fusion)—Also called ATP (anterior to psoas). This is done with an oblique anterolateral retroperitoneal route with entry to the disc anterior to the psoas. It can be done from L2–S1 levels

Of course, a question may be asked as to how OLIF or anterior approaches treat the pathology (canal stenosis or spondylolisthesis) if we are not entering the canal and not removing any bone or ligament from the spine. The mechanism by which OLIF treats these conditions is “indirect decompression” (in contrast to direct decompression in other techniques). Indirect decompression is achieved by doing “uniform disc space distraction” and “ligamentotaxis.” OLIF places a large cage across the entire disc space achieving uniform disc distraction and achieves ligamentotaxis as it preserves all ligaments of the spine. This helps in stretching the bulging disc and buckled ligamentum flavum and increasing spinal canal diameter

and hence results in spinal decompression. Since the spinal canal is not entered directly in OLIF, this mechanism is called “indirect decompression” (6–9).

## 2. Indications

Anterior and lateral approaches to the lumbar spine can be considered in the following cases:

1. Grade 1 and 2 spondylolistheses (? Grade 3)
  - a. Degenerative
  - b. Lytic
2. Lumbar canal stenosis with no severe “central” stenosis (cases that necessitate fusion in absence of instability)
3. Degenerative scoliosis with asymmetrical lateral recess or foraminal stenosis
4. Discogenic pain necessitating surgery
5. Pseudoarthrosis after failed PLF
6. Post-infective instability with no active disease/epidural compression

While an anterior approach (ALIF or OLIF 51) is preferable at L5-S1 and in some cases at L4–L5, a lateral approach can be chosen for L1–L5 levels.

## 3. Contra-indications

The following group of conditions are not suitable for an anterior or a lateral approach:

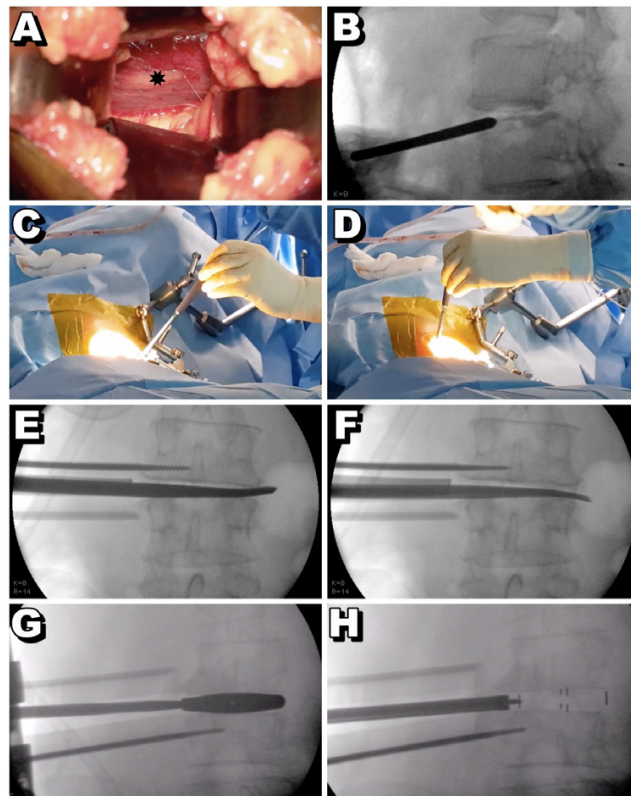
1. Unfavorable approach related concerns
  - a. Insufficient gap between the anterior border of psoas and aorta/common iliac vessels
  - b. Previous retroperitoneal surgery
  - c. Transitional vertebra with abnormally high iliac crest (may interfere with orthogonal maneuver)
2. Conditions where disc space distraction cannot be achieved (mobility/flexibility of segment is reduced)



- a. Calcified/severely arthritic facets or annulus
  - b. Chronic cases with ALL shortening/calcification
  - c. Lateral/anterior bridging osteophytes
- 3. Conditions where disc space distraction is not effective in treating pathology and requires direct decompression
  - a. Severe central canal stenosis
  - b. Hypertrophied medial lip of superior articular process causing lateral recess stenosis
- 4. Complex pathologies (relative contraindications)
  - a. High-grade listhesis
  - b. Severe scoliosis (coronal Cobb angle  $>40^\circ$ ; severe rotational curve; lateral listhesis  $>15$  mm)
  - c. Above L1

## 4. Technique

Figure 2, the patient is positioned in right lateral decubitus position with adequate padding for relevant pressure points. The dependent (right) leg is flexed and the left leg is kept extended to keep the psoas muscle taut. Under fluoroscopic guidance, a skin incision is marked approximately 5–8 cm in front of the target disc space. In a two-level approach, the incision can be placed in between the target disc spaces in front of the vertebral body. After painting and draping, the incision is deepened to expose the external oblique fascia, which is the only layer that needs to be incised along the length of the incision. Further to that, the external oblique, internal oblique, and transversus abdominis muscles are dissected along the direction of their respective fibers to expose the retroperitoneal fat. Once retroperitoneal fat is identified, blunt dissection with finger or peanut on a forceps is used to separate the fat anteriorly and make a plane between the posterior abdominal wall and retroperitoneal fat extending deeper all the way to the surface of the psoas muscle. Dissection is further extended along the surface of the psoas muscle to identify the anterior border of the psoas and the disc space in front of it. The correct level and entry point is confirmed on fluoroscopy and the expandable retractor is docked on the anterior one-third to one-fourth of the disc space after serial dilatation. A block annulotomy is done and the disc and endplate are removed using rongeurs/curettes/shavers as per one's convenience.



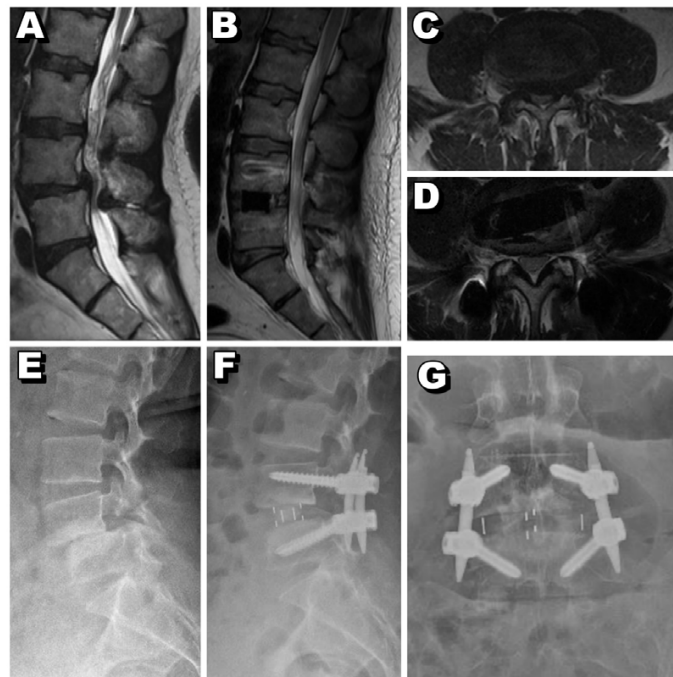
**Figure 2** | Intra-operative representative images to illustrate the important steps in OLIF. (A) Retroperitoneal exposure of the psoas muscle (\*). (B) Lateral fluoroscopic image confirming the entry into the target disc in its anterior one-fourth. (C,D) Starting position (C) and final position (D) in an orthogonal maneuver. (E,F) AP fluoroscopic image while performing contralateral annular release both superiorly (E) and inferiorly (F) using a Cobb's elevator. (G) Trial insertion. (H) Final cage insertion.

Due to the oblique trajectory, it is important to realign the instruments upon entering the disc space so that as we progress deeper, the instrument becomes perpendicular to the ground or in other words, co-axial to the long axis of the disc. This will prevent the instruments from breaching into the contralateral foraminal zone and position the cage along the long axis of the disc. This step, called “The Orthogonal Maneuver,” is the most important step in OLIF and has to be performed at each step of disc preparation, contralateral annular release, trial insertion, and final cage placement.

Once adequate disc and endplate preparation is done, the contralateral annulus is released from its lateral vertebral attachment, both superiorly and inferiorly, using a Cobb's elevator. An appropriately sized trial is selected and if needed, sequentially increasing trial sizes are inserted to achieve disc space distraction. The final cage size is

then selected, filled with an optimal and appropriate graft and inserted into the disc space. The transversalis and external oblique fascia are closed with intermittent sutures and wound closed in layers.

It is standard of care to supplement the interbody cage with posterior percutaneous pedicle screws. Once the cage insertion is completed, the patient can be turned prone to place percutaneous pedicle screws. Alternatively, pedicle screws can be placed in lateral position as well (Figure 3).

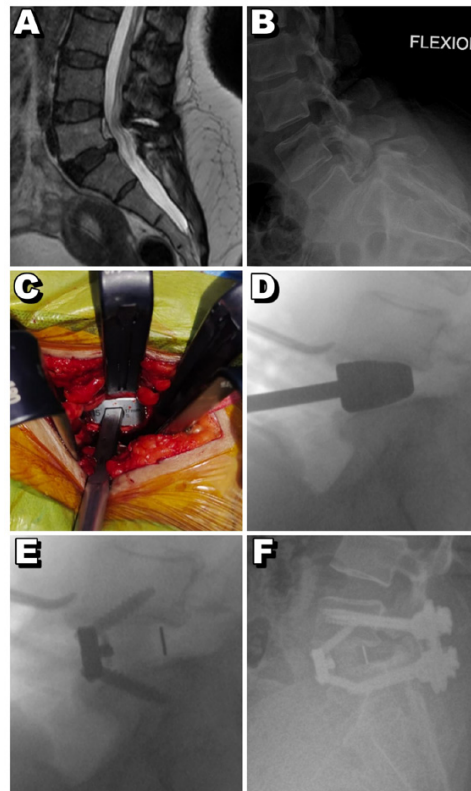


**Figure 3** | Clinical case example of an L4-5 OLIF with posterior percutaneous pedicle screw fixation. (A,B) Pre-operative (A) and post-operative (B) sagittal T2W image. (C,D) Pre-operative (C) and post-operative (D) T2W axial image. (E,F) Pre-operative (E) and post-operative (F) lateral (standing) radiographs. (G) Post-operative AP radiograph. The increase in disc and foraminal height and restoration of spinal canal dimensions can be appreciated.

## 5. OLIF L5-S1

While doing an OLIF at L5-S1, the incision is placed more anteriorly and inferiorly (8–10 cm in front of the anterior superior iliac spine. After abdominal layer and retroperitoneal dissection in a manner described above to reach the surface of the psoas, the left common iliac vessels can be identified and included in a retractor blade which can either be attached to a flex arm triblade assembly or

fixed onto the sacrum using a stabilizing pin. Further blunt dissection on the surface of the L5-S1 disc is done to sweep the soft tissue along with the hypogastric plexus away to the other side. Though infrequently identified, contralateral iliac vessels can be sometimes visualized and another retractor blade is placed on the far side (right side) of the L5-S1 disc space. If needed, a third retractor blade can be placed to move the aortic and venacaval bifurcation and protect it superiorly. Further steps of annulotomy, discectomy, endplate preparation, disc space distraction with sequential trials, and insertion of an appropriate final cage are done. The L5-S1 cage should always be augmented with an anterior plate and screw or stand-alone screw inserted through the cage (Figure 4).



**Figure 4** | Clinical case example of L5-S1 ALIF with posterior percutaneous pedicle screw fixation. **(A)** Pre-operative T2W sagittal MRI image showing a wedge-shaped L5-S1 disc space with restored alignment [compared to standing X-ray **(B)**]. **(B)** Pre-operative standing flexion lateral radiograph showing an unstable L5-S1 spondylolisthesis. **(C)** Intra-operative anterior retroperitoneal exposure to the L5-S1 disc space with retractors in place and trial inserted in to the disc space. **(D)** Lateral intra-operative fluoroscopic image showing the trial cage in place. **(E)** Lateral intra-operative fluoroscopic image after planning the final cage and screws (inserted through slots in the cage) achieving complete reduction of listhesis. **(F)** Final lateral post-operative radiograph showing the anterior cage with screws along with posterior percutaneous screws.

## 6. Clinical outcomes

OLIF has proved to be a safe and effective technique with complication profile and clinical outcomes superior to those of transpsoas approaches. Lateral approaches result in less blood loss, post-operative pain as compared to posterior approaches. The degree of disc height restoration, foraminal height restoration, and sagittal or coronal balance restoration is significantly better with lateral approaches as compared to posterior approaches (8, 9). An ATP approach avoids the high incidence of hip flexion weakness and thigh/groin paresthesias encountered with transpsoas approaches (10–12). Even the genitofemoral nerve (GFN), which runs on the surface of the psoas muscle can be directly visualized in most cases and preserved while dissection. A systematic review of 16 studies with 1,453 patients placed an overall incidence of intra-operative and post-operative complication of 1.5 and 9.9%, respectively (13). The common post-operative complications were cage subsidence, transient thigh pain/numbness, transient hip flexion weakness (1–2%), and post-operative ileus (common after L5-S1) (6, 14). Though case reports exist, the incidence of ureteral or major vascular injury in OLIF at L2-L5 levels is very low (<1%) (14). The incidence of vascular injury is relatively high (2–8%) while operating at L5-S1 (15).

## 7. Summary

Anterior and lateral approaches provide a suitable and, in some instances, superior alternative to the standard and widely practiced posterior approaches. They are outside the canal approaches, which rely on indirect decompression and uniform interbody distraction to achieve superior disc and foraminal height restoration as compared to posterior approaches. In the present era of spine surgeons' effort to achieve the optimal spinal balance in fusion surgeries, the anterior and lateral approaches are indispensable tools to maintain or restore sagittal and coronal spinal balance, and should ideally be part of every spine surgeon's armamentarium.

## References

1. Wu WJ, Liang Y, Cao P, Zhang XK, Zheng T, Qiu JR. Minimally invasive lateral lumbar interbody fusion significantly improves the sagittal balance for adult



- degenerative scoliosis. *Zhonghua Yi Xue Za Zhi.* (2020) 100(3):192–196. doi: 10.3760/cma.j.issn.0376-2491.2020.03.007
2. Champagne P-O, Walsh C, Diabira J, Plante M-É, Wang Z, Boubez G, et al. Sagittal balance correction following lumbar interbody fusion: a comparison of the three approaches. *Asian Spine J.* (2019) 13(3):450–458. doi: 10.31616/asj.2018.0128
3. Li R, Shao X, Li X, Liu Y, Jiang J. Comparison of clinical outcomes and spino-pelvic sagittal balance in degenerative lumbar spondylolisthesis: minimally invasive oblique lumbar interbody fusion (OLIF) versus transforaminal lumbar interbody fusion (TLIF). *Medicine.* (2021) 100(3): e23783. 10.1097/MD.00000000000023783
4. Yoon J, Choi HY, Jo DJ. Comparison of outcomes of multi-level anterior, oblique, transforaminal lumbar interbody fusion surgery: impact on global sagittal alignment. *J Korean Neurosurg Soc.* (2023) 66(1): 33–43. doi: 10.3340/jkns.2022.0112
5. Ohtori S, Orita S, Yamauchi K, Eguchi Y, Ochiai N, Kishida S, et al. Mini-open anterior retroperitoneal lumbar interbody fusion: oblique lateral interbody fusion for lumbar spinal degeneration disease. *Yonsei Med J.* (2015) 56(4):1051–1059. doi: 10.3349/ymj.2015.56.4.1051
6. Mobbs RJ, Phan K, Malham G, Seex K, Rao PJ. Lumbar interbody fusion: techniques, indications and comparison of interbody fusion options including PLIF, TLIF, MI-TLIF, OLIF/ATP, LLIF and ALIF. *J Spine Surg.* (2015) 1(1):2–18. doi: 10.3978/j.issn.2414-469X.2015.10.05
7. Lin G-X, Akbary K, Kotheeranurak V, Quillo-Olvera J, Jo H-J, Yang X-W, et al. Clinical and radiologic outcomes of direct versus indirect decompression with lumbar interbody fusion: a matched-pair comparison analysis. *World Neurosurg.* (2018) 119:e898–e909. doi: 10.1016/j.wneu.2018.08.003
8. Shimizu T, Fujibayashi S, Otsuki B, Murata K, Matsuda S. Indirect decompression via oblique lateral interbody fusion for severe degenerative lumbar spinal stenosis: a comparative study with direct decompression transforaminal/posterior lumbar interbody fusion. *Spine J.* (2021) 21(6):963–971. doi: 10.1016/j.spinee.2021.01.025
9. Elowitz E, Yanni D, Chwajol M, Starke R, Perin N. Evaluation of indirect decompression of the lumbar spinal canal following minimally invasive lateral transpsoas interbody fusion: radiographic and outcome analysis. *Minim Invasive Neurosurg.* (2012) 54(05/06):201–206. doi: 10.1055/s-0031-1286334
10. Dahdaleh NS, Smith ZA, Snyder LA, Graham RB, Fessler RG, Koski TR. Lateral transpsoas lumbar interbody fusion: outcomes and deformity correction. *Neurosurg Clin N Am.* (2014) 25(2):353–360. doi: 10.1016/j.nec.2013.12.013
11. Moller DJ, Slimack NP, Acosta FL, Koski TR, Fessler RG, Liu JC. Minimally invasive lateral lumbar interbody fusion and transpsoas approach-related morbidity. *Neurosurg Focus.* (2011) 31(4):E4. doi: 10.3171/2011.7.FOCUS11137
12. Ahmadian A, Deukmedjian AR, Abel N, Dakwar E, Uribe JS. Analysis of lumbar plexopathies and nerve injury after lateral retroperitoneal transpsoas approach: diagnostic standardization. *J Neurosurg Spine.* (2013) 18(3):289–297. doi: 10.3171/2012.11.SPINE12755
13. Li JXJ, Phan K, Mobbs R. Oblique lumbar interbody fusion: technical aspects, operative outcomes, and complications. *World Neurosurg.* (2017) 98:113–123. doi: 10.1016/j.wneu.2016.10.074

14. Hah R, Kang HP. Lateral and oblique lumbar interbody fusion—current concepts and a review of recent literature. *Curr Rev Musculoskelet Med.* (2019) 12(3):305–310. doi: 10.1007/s12178-019-09562-6
15. Quraishi NA, Konig M, Booker SJ, Shafafy M, Boszczyk BM, Grevitt MP, et al. Access related complications in anterior lumbar surgery performed by spinal surgeons. *Eur Spine J.* (2013) 22(Suppl 1):S16–S20. doi: 10.1007/s00586-012-2616-1





# Minimally invasive surgery for cervical and thoracic spine

---

**Saransh Gupta, Hitesh Inder Singh Rai  
and Sachin A. Borkar**

Department of Neurosurgery,  
All India Institute of Medical Sciences, New Delhi, India

1. Introduction .....	94
2. Minimally invasive anterior foraminotomy for cervical radiculopathy .....	94
2.1. Indications .....	95
2.2. Limitations .....	95
2.3. Description of anatomy .....	95
2.4. Surgical technique .....	96
2.5. Postoperative care .....	97
2.6. Complications .....	97
2.6.1. Nerve root injury .....	97
2.6.2. Vertebral artery injury .....	98
2.6.3. Horner's syndrome .....	98
2.6.4. Epidural bleeding .....	98
2.6.5. Summary .....	98
3. Minimally invasive posterior foraminotomy/ laminotomy for nerve root decompression .....	99
3.1. Indications .....	99
3.2. Limitations .....	99
3.3. Operative technique .....	99
3.4. Complications .....	100
4. Conclusion.....	101
5. Minimally invasive treatment of thoracic disc herniation .....	101
5.1. Preoperative evaluation.....	101

## Minimally invasive surgery for cervical and thoracic spine 94

5.2.	Microendoscopic and microscopic discectomy .....	101
5.3.	Indications: Soft lateral thoracic disc herniation .....	102
5.4.	Transforaminal endoscopic disc removal.....	102
5.4.1.	Indication.....	102
5.4.2.	Technique .....	102
5.4.3.	Complications.....	103
	References.....	103

## 1. Introduction

Minimally invasive spine surgery has gained popularity over the last several decades. The proposed benefits of these approaches include less muscle trauma and tissue dissection, scarring, blood loss, pain, faster patient recovery, and potentially better (or at least equivalent) clinical outcomes. This chapter is focused on the minimally invasive techniques in cervical and thoracic spine surgery and has been written in three sections:

- Minimally invasive anterior foraminotomy for cervical radiculopathy
- Minimally invasive posterior foraminotomy/laminotomy for nerve root decompression
- Minimally invasive treatment of thoracic disc herniation

## 2. Minimally invasive anterior foraminotomy for cervical radiculopathy

The most common surgical procedure performed for cervical radiculopathy secondary to disc herniation or osteophytosis is anterior cervical discectomy and fusion (ACDF) (1). The drawback of this procedure however, is fusion of a motion segment with potential for adjacent segment degeneration and disease (2).

As an alternative, anterior cervical foraminotomy allows direct nerve root decompression with preservation of segmental motion. The technique was first described by Jho (3) in 1996 whereby the transverse process and uncovertebral joint were exposed and the decompression was performed through the gradual removal of the uncinat process. Since the original description by Jho, there have been several modifications to this procedure (4, 5).

## 2.1. Indications

Unilateral cervical radiculopathy secondary to soft disc prolapse or osteophytes at one or two adjacent levels.

## 2.2. Limitations

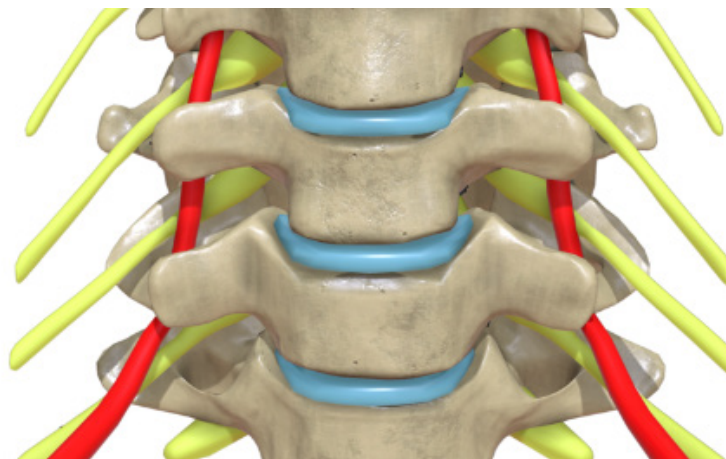
- Myelopathy
- Bilateral symptoms
- Polysegmental pathology
- Segmental instability or kyphosis

These may benefit from standard ACDF (6)

## 2.3. Description of anatomy

The target area (uncovertebral foraminal region) is limited by the following structures (Figure 1):

- transverse process—anterior and lateral
- uncinate process—medial
- articular processes—posterior
- inferior aspect of the upper pedicle—superior (7).



**Figure 1** | Representing the anatomy of the uncovertebral foraminal region of the subaxial cervical spine.

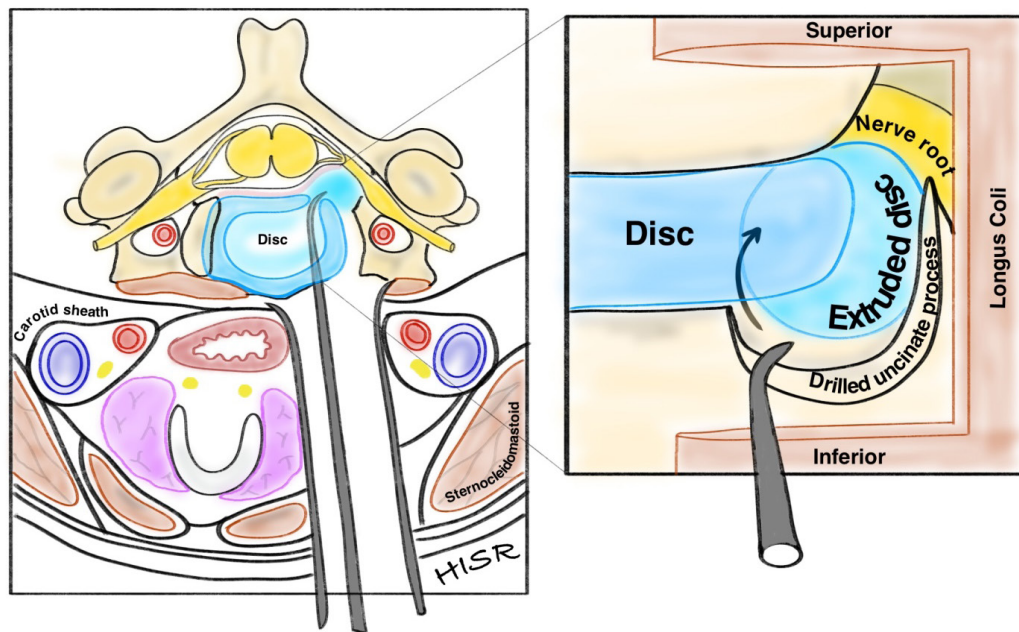
The nerve root is found in the lower third of the space with the apex of the uncinate process (UP) being above each root. The vertebral artery is located in the anterolateral aspect for the uncovertebral

foramen region. The distance between the medial margin of the foramen transversarium in which the vertebral artery and veins travel and the uncinat process increases from C3 to C7 (0.6 mm at C2–C3 to 1.6 mm at C4–C5) (8).

## 2.4. Surgical technique

The operation is performed with the patient under general anesthesia on a standard operating room table. The patient is positioned supine with the neck in a slight extension and a gel cushion behind the shoulders. The vertebral level and site of surgery is confirmed with an image intensifier. A 3 cm transverse skin incision (2/3 medial and 1/3 lateral over the medial border of sternocleidomastoid muscle) is made over the segment. Platysma is incised along the line of skin incision. The anterior aspect of the subaxial spine is opened in the standard manner reaching up to the prevertebral fascia. The prevertebral fascia is opened and anterior part of vertebral bodies, intervertebral disc, and the longus colli is exposed at the target level after confirming under image intensifier. A thumbnail portion of the longus colli muscle is resected to expose the uncovertebral joint from the base of one TP to the base of the TP below. An appropriately sized tubular retractor is placed, centered over the uncovertebral joint parallel to the index disc space. Care must be taken at C7, where the vertebral artery runs between the transverse process and the longus colli muscle. An operating microscope is now utilized to perform the remaining steps of the procedure. The operative field of view includes the lateral aspect of the intervertebral disc, the lateral portion of the cephalad vertebral body, and the lateral portion of the caudal vertebral body and the uncinat process. A high-speed drill with a 3 mm matchstick cutting burr is used to initiate the drilling of the uncinat process preserving the lateral border of the uncinat process to protect the vertebral artery. Once the posterior cortical layer is reached, a 2 mm diamond burr is used. The thin posterior cortical layer is carefully drilled under constant irrigation. The periosteum and fibrous tissue between the uncinat and superior and inferior endplates is removed with 1 mm Kerrison rongeur. Posterolateral disc herniation may be visible at this stage in front of the nerve root and can be removed with microhook and micro-punch. The posterior longitudinal ligament is opened with a microsurgical hook and a 1-mm Kerrison and any hidden herniated disc

fragment retrieved. The nerve root can now be visualized in entirety and confirmed with a microsurgical hook passed into the foramen superiorly and inferiorly to the nerve root. After the hemostasis, the tubular retractor is removed, and the platysma is approximated with absorbable sutures. The skin incision is closed with intradermal 4.0 suture. No drain is necessary in most cases. An illustrative figure is shown in Figure 2.



**Figure 2** | The minimally invasive anterior cervical foraminotomy technique. An axial image showing the approach. (In subset: an anterior view as seen through the tubular retractor).

## 2.5. Postoperative care

The patient is mobilized 6–8 h postoperatively and advised to limit vigorous neck movements for 2 weeks. At follow-up, static and dynamic X-rays at 6 weeks, 6 months, and 1 year are recommended.

## 2.6. Complications

### 2.6.1. Nerve root injury

The nerve root is located posterolateral to the uncinate process, with PLL between the two structures. Careful drilling and leaving a small

chip of bone posteriorly, which can be removed with micro curette of Kerrison, can help prevent accidental injury to the nerve root.

### **2.6.2. Vertebral artery injury**

It is most vulnerable to injury at C6-C7 level, where the artery travels between process of C7 the longus colli muscle and the transverse process of C7. The incision of the longus colli muscle should therefore be performed proximal to the transverse process of C6. The artery can subsequently be identified by careful dissection proceeding caudally. The MRI angiogram should be evaluated to rule out anomalous course of the vertebral artery. The vertebral artery is also at risk at its location lateral to the uncinate process. However, retaining the lateral and anterior aspects of the uncinate process during the approach, the vertebral artery should remain protected.

### **2.6.3. Horner's syndrome**

The sympathetic chain lies along the lateral border of the longus colli muscle. By limiting the lateral dissection and retraction of the muscle to medial border of anterior tubercle of the transverse process, this complication can be avoided.

### **2.6.4. Epidural bleeding**

This occurs most commonly when the PLL is taken down and can obscure the surgical field. Bipolar cautery and hemostatic agents are used to control the bleeding. Care must be taken not to leave them inside upon closing since they have the potential to swell up and cause nerve compression.

### **2.6.5. Summary**

It is an effective technique for the treatment of unilateral radiculopathy resulting from soft disc herniation or foraminal stenosis due to uncovertebral osteophytes. There is a learning curve to it and experience with microscopic procedures and familiarity with microscopic anatomy of the region is important. Avoiding damage to a large portion of the lateral aspect of the disc space is the key to the long-term success of this procedure.



### **3. Minimally invasive posterior foraminotomy/laminotomy for nerve root decompression**

#### **3.1. Indications**

Indications for cervical surgery by any approach include unremitting pain despite maximal conservative therapy and/or a progressive neurological deficit, especially weakness (9).

- Posterolateral soft disc herniation,
- Isolated spondylotic foraminal stenosis,
- Persistent radiculopathy despite previous anterior cervical discectomy and fusion.

The ideal patient for this technique has nerve pinched between the uncinat process and the facet; opening the dorsum of the neuroforamen will yield a successful outcome. On clinical examination such a patient should have symptoms reproducible on Spurling's test and should improve on forward flexion of the neck.

#### **3.2. Limitations**

- Myelopathy
- Central or paracentral stenosis secondary to a soft disc or osteophytic origin,
- Deformity or instability,

In such cases the laminoforaminotomy technique may not be the ideal procedure

#### **3.3. Operative technique**

Under general anesthesia, the patient is log rolled into prone position. Mayfield is used to hold the head, and neck is slightly flexed. The table is tilted in a reverse Trendelenburg position so that the neck is parallel to the floor. Target level is marked using an image intensifier and a 3 cm longitudinal incision given just off the midline. Fascia is opened sharply and a blunt dilator is advanced under image guidance toward the lamina and lateral mass junction over the target level. Sequential dilators followed by final tubular retractor is locked

in position and confirmed radiologically. A microscope is brought in at this stage. A high-speed burr is used for laminotomy and resection of medial half of the facet. Once thinned to the underlying cortical margin, a small-angled curette or 1 mm Kerrison is used to remove the remaining bone. The amount of facet joint resection should not exceed 50% in order to preserve spinal stability (10). Ligament flavum is identified and opened at the laminar portion carefully using Kerrison and nerve hook. Care is taken not to disrupt the venous plexus. The nerve root is exposed and soft disc fragments can be retrieved using a no. 11 blade and pituitary rongeur, after elevation of the root. Thorough exploration is conducted above, below, and medial to the nerve to ensure that all fragments have been removed. A nerve hook can be passed into the foramen to confirm adequate room for the nerve root. The site is thoroughly irrigated and hemostasis achieved with bipolar cautery and fascia and skin closed.

Patients can usually be discharged after 24 h on oral analgesics. The need for soft collar is optional. Early mobilization is encouraged.

### **3.4. Complications**

Nerve root injury – Either direct injury as a result of it being mistaken for a disc or due to the insertion of instruments in the stenotic space or secondary to retraction of the nerve root and traction injury. Edema resulting from revascularization of an ischemic nerve root can also be responsible for it (11).

Incidental durotomy can be managed by placing a small pledget of hemostatic agent at the site followed by a dural sealant; however, persistent leak requires direct repair and lumbar drain.

Postoperative instability can be prevented by careful patient selection and preservation of the lateral half of the facet joint (12).

Injury to the vertebral artery is exceedingly rare but potentially one of the more serious complications (13). CT/MRI angiogram should be carefully visualized to pick up abnormal artery course.

Recurrence of symptoms has been reported and appears to be more common with longer follow-up (14, 15). This may be because of incomplete decompression initially, scarring as a result of surgery or post-operative abscess.

Infection is quite uncommon following tubular-based decompression. Traditional techniques of debridement and decompression should be pursued.

## **4. Conclusion**

Minimally invasive cervical posterior decompression for foraminal stenosis secondary to soft disc herniation or bony compression is a useful technique, provided there is no stability, fixed kyphosis, or significant axial neck pain. There is a learning curve to this procedure; however, it is possible to achieve equivalent results with reduced morbidity compared to traditional open surgery (16, 17).

## **5. Minimally invasive treatment of thoracic disc herniation**

The incidence of thoracic disc herniation is much lower than that of lumbar and cervical disc herniations. Though these can be a challenging pathologic abnormality, they can be treated minimally invasively as multiple techniques have been developed. Knowledge of thoracic spinal anatomy is critical for the safe application of surgical techniques for thoracic disc treatment.

### **5.1. Preoperative evaluation**

Calcification is present in about 30–70% of thoracic disc herniations (18). Central and calcified discs in general are approached through lateral extra-cavitary or a transthoracic approach, while paracentral and soft discs are approached through a posterolateral approach. Giant thoracic disc (occupying more than 40% of the canal diameter on MRI) indicates a surgical challenge and may not be suitable for minimally invasive procedures (19). The preoperative MRI should include imaging that allows the surgeon to determine the correct herniated thoracic disc level counting from C2 down or from the sacrum up.

### **5.2. Microendoscopic and microscopic discectomy**

This technique was described by Perez-Cruet et al. (20) in 2004 and further evaluated by Issacs et al. (21). They demonstrated that a sufficient amount of the thoracic disc herniation could be removed with average facet removal of 35.5%. As the procedure retained a large part of the facet and the native disc, fusion was not necessary.

### **5.3. Indications: Soft lateral thoracic disc herniation**

The procedure is as follows: (1) Positioning – Prone position under general anesthesia (2) Incision - 4 cm lateral to the midline and the initial dilator is docked over the superior aspect of the base of the caudal transverse process. Subsequently, sequential dilators are placed followed by an 18- or a 20-mm tubular retractor. (3) Monopolar cautery is used to dissect the soft tissues of the lateral facet and the proximal transverse process. (4) The medial portion of the facet complex could be removed with a high-speed drill, and then the pedicle could be removed over the disc space. (5) After drilling the superior aspect of the pedicle, the foraminal bleeding is controlled with bipolar cautery. (6) The exiting nerve root is carefully dissected and the disc herniation is removed using nerve hook and disc forceps. (7) The wound is closed in layers after adequate hemostasis.

### **5.4. Transforaminal endoscopic disc removal**

The procedure was first described by Choi et al. (22). Transforaminal endoscopic thoracic discectomy (TETD) has been implemented as an alternative to classic open procedures with results that are as good as those of traditional open discectomy.

The procedure is similar to transforaminal endoscopic discectomy in lumbar spine with added foraminoplasty.

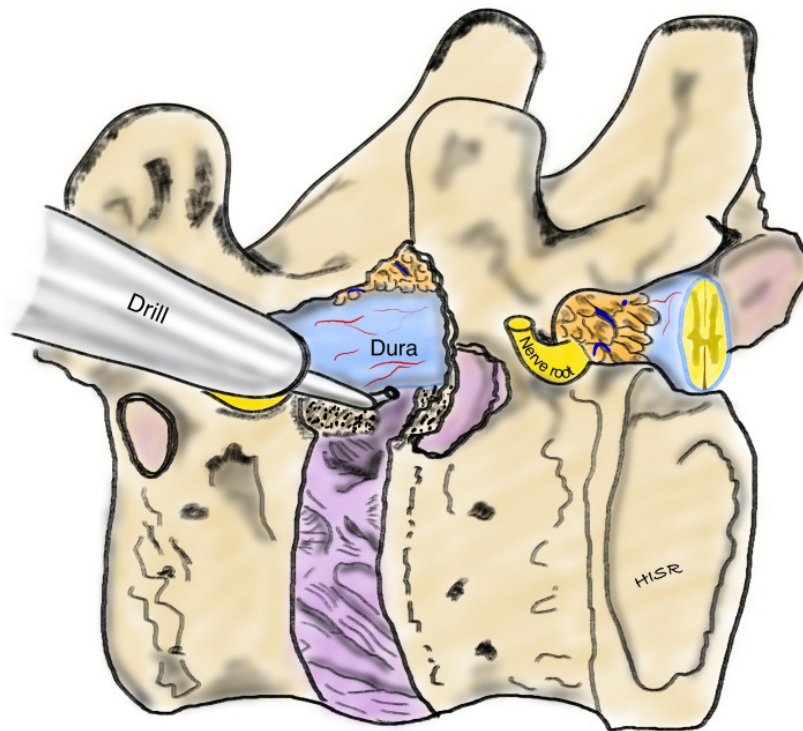
#### **5.4.1. Indication**

Soft paracentral disc herniation. It can be done under local anesthesia.

#### **5.4.2. Technique**

The patient is placed prone under mild sedation, and the entry point is marked based on preoperative axial MRI, the angulation being approximately 45°. Under fluoroscopy guidance, the guide wire is inserted targeting the disc space of interest. The position of guide-wire should be just medial to medial border of pedicle on AP view and just anterior to posterior vertebral border on lateral view. After local infiltration, the needle is advanced into the disc space and discography is done. Sequential reamers are passed to shave the ventral aspect of the superior facet. Beveled cannula and endoscope are inserted and using endoscopic forceps, the herniated disc is

removed under visualization. At the end of the procedure, one of the signs that help us to confirm the proper decompression is the free movement of the thecal sac by changing the irrigation pressure. An illustrative figure is shown in Figure 3.



**Figure 3** | Transforaminal endoscopic thoracic discectomy (side on view).

### 5.4.3. Complications

Vascular and pulmonary complications occur when the position of the needle locates more toward lateral. Complications such as nerve injuries, intercostal neuralgias, and dural tears might happen when the needle moves very medially. Other complications such as recurrence of herniations, residual fragments of discs, and heat injury might also occur; the latter, more frequently related to the use of laser and radiofrequency.

## References

1. Nguyen J, Chu B, Kuo C, Leasure J, Ames C, Kondrashov D. Changes in foraminal area with anterior decompression versus keyhole foraminotomy in the cervical spine: a biomechanical investigation. *J Neurosurg Spine*. (2017) 27:620–6. doi: 10.3171/2017.2.SPINE141237

2. Zou S, Gao J, Xu B, Lu X, Han Y, Meng H. Anterior cervical discectomy and fusion (ACDF) versus cervical disc arthroplasty (CDA) for two contiguous levels cervical disc degenerative disease: a meta-analysis of randomized controlled trials. *Eur Spine J.* (2017) 26:985–97. doi: 10.1007/s00586-016-4655-5
3. Jho H. Microsurgical anterior cervical foraminotomy for radiculopathy: a new approach to cervical disc herniation. *J Neurosurg.* (1996) 84:155–60.
4. Jho H, Kim W, Kim M. Anterior microforaminotomy for treatment of cervical radiculopathy: Part 1—Disc-preserving “functional cervical disc surgery.”. *Neurosurgery.* (2002) 51:46–53.
5. Saringer W, Nöbauer I, Reddy M, Tschabitscher M, Horaczek A. Microsurgical anterior cervical foraminotomy (uncoforaminotomy) for unilateral radiculopathy: clinical results of a new technique. *Acta Neurochir.* (2002) 144:685–94.
6. Jho H. Failed anterior cervical foraminotomy. *J Neurosurg.* (2003) 98:121–5.
7. Yilmazlar S, Kocaeli H, Uz A, Tekdemir I. Clinical importance of ligamentous and osseous structures in the cervical Acta Neurochir uncovertebral foraminal region. *Clin Anat.* (2003) 16:404–10. doi: 10.1002/ca.10158
8. Pait T, Killefer J, Arnautovic K. Surgical anatomy of the anterior cervical spine: the disc space, vertebral artery, and associated bony structures. *Neurosurgery.* (1996) 39:769–76. doi: 10.1097/00006123-199610000-00026
9. Roh S, Kim D, Cardoso A, Fessler R. Endoscopic foraminotomy using MED system in cadaveric specimens. *Spine.* (2000) 25:260–4.
10. Grundy P, Germon T, Gili S. Transpedicular approaches to cervical uncovertebral osteophytes causing radiculopathy. *J Neurosurg.* (2000) 93:21–7.
11. Zeidman S, Ducker T. Posterior cervical laminoforaminotomy for radiculopathy: review of 172 cases. *Neurosurgery.* (1993) 33:356–62.
12. Raynor R, Pugh J, Shapiro L. Cervical facetectomy and its effect on spine strength. *J Neurosurg.* (1985) 63:278–82.
13. Harrop J, Silva M, Sharan A, Dante S, Simeone F. Cervicothoracic radiculopathy treated using posterior cervical foraminotomy/disectomy. *J Neurosurg.* (2003) 98:131–6.
14. Woertgen C, Holzschuh M, Rotboerl R, Hueusler E, Brawanski A. Prognostic factors of posterior cervical disc surgery: a prospective consecutive study of 54 patients. *Neurosurgery.* (1997) 40:724–8.
15. Jodicke A, Daentzer D, Kastner S, Asamoto S, Boker D. Risk factors for outcome and complications of dorsal foraminotomy in cervical disc herniation. *Surg Neurol.* (2003) 60:124–9.
16. Adamson T. Microendoscopic posterior cervical laminoforaminotomy for unilateral radiculopathy: results of a new technique in 100 cases. *J Neurosurg.* (2001) 95(Suppl. 1):51–7.
17. Kim K, Kim Y. Comparison between open procedure and tubular retractor assisted procedure for cervical radiculopathy: results of a randomized controlled study. *J Korean Med Sci.* (2009) 24:649–53.
18. Burkett C, Greenberg M. Cervical and thoracic spine degenerative disease. In: Baaj A, Mummaneni P, Uribe J editors. *Handbook of spine surgery.* New York, NY: Thieme Medical Publishers (2012).
19. Strom RG, Mathur V, Givans H, Kondziolka DS, Perin NI. Technical modifications and decision-making to reduce morbidity in thoracic disc surgery: an



- institutional experience and treatment algorithm. *Clin Neurol Neurosurg.* (2015) 133:75–82.
20. Perez-Cruet MJ, Kim B, Sandhu F, Samartzis D, Fessler RG. Thoracic microendoscopic discectomy. *J Neurosurg Spine.* (2004) 1:58–63.
  21. Isaacs RE, Podichetty VK, Sandhu FA, Santiago P, Spears JD, Aaronson O, et al. Thoracic microendoscopic discectomy: a human cadaver study. *Spine.* (2005) 30:1226–31.
  22. Choi KY, Eun SS, Lee SH, Lee HY. Percutaneous endoscopic thoracic discectomy; transforaminal approach. *Minim Invasive Neurosurg.* (2010) 53:25–8.



# Advanced applications and future directions

---

**Ashutosh Kumar and Jayesh Sardhara**

Fortis Hospital, Mumbai, India

1. Introduction .....	107
2. Navigation technologies.....	108
2.2. Single or biplanar fluoroscopy (non-navigated).....	109
2.2. Navigated two-dimensional fluoroscopy.....	109
2.3. Fan beam and cone beam computed tomography-based three-dimensional navigation ....	110
2.4. 3D “total navigation” .....	110
3. Advances in optics and visualization technology .....	111
4. Instruments and implants .....	111
4.1. Drill .....	111
4.2. Expandable cages .....	112
4.3. Energy sources .....	112
4.4. Expansion of MISS applications with advanced technology .....	112
4.5. Future perspective .....	113
5. Robotics and artificial intelligence.....	113
5.1. Augmented and virtual reality.....	114
5.2. Nanotechnology and photonics .....	115
5.3. Conclusion.....	116
References .....	116

## 1. Introduction

Precise and accurate intervention in spinal diseases can relieve the symptoms while ensuring minimum collateral damage to normal anatomical structures, thus improving the surgical outcome as well

as minimizing possible future complications. This ideology is the basis of minimally invasive spine surgery (MISS). Its practice has resulted in the development of a special sect of cutting-edge spine surgeons who continuously strive for improvement in the technique by incorporating novel technologies, which in turn has led to a technological boom in the last few decades in the field of MISS. MISS is based on three fundamental pillars (1). Navigation, (2). Optics, and (3). Instruments. There has been immense advancement in all these three workhorses.(1) Advancement in one subset paved the way for improvement in another, propelling MISS to more advanced status. It has allowed an expansion of current applications of minimally invasive surgery in the spine, with more safety and better outcome due to better accuracy and precision.

In optics, endoscopes have proved to be better than microscopes in realizing the aims of MISS. Thus, currently all efforts are being made in the process of further enhancing the capabilities of the endoscope. Navigation systems have advanced in leaps and bounds with the improvement in imaging technology and software. Specially curated instruments, as well as implants, have improved maneuverability during the MISS procedures. Development in these fields has formed the foundation for the inclusion of robotics and virtual reality in MISS. This article deals with the recent advent in the field of MISS and the vast opportunities for its applications for other spinal pathologies.(2, 3, 4)

## **2. Navigation technologies**

The recent advances in navigation techniques amalgamate the surgeon's knowledge of anatomical relationships and real-time visualization of anatomical structures to perform accurate implant insertion or surgical decompression while minimizing the need for direct visualization. It includes two components. Firstly, the imaging modality, and secondly the navigation technology, which gives real-time guidance for instrumentation. Over the last few decades, there has been tremendous advancement in the field of navigation due to the application of software technology in developing real-time 2D or 3D images of anatomical structures from the raw input from radiological imaging. The gamut of navigation technologies includes single or biplanar fluoroscopy (non-navigated), navigated two-dimensional fluoroscopy, three-dimensional navigation based

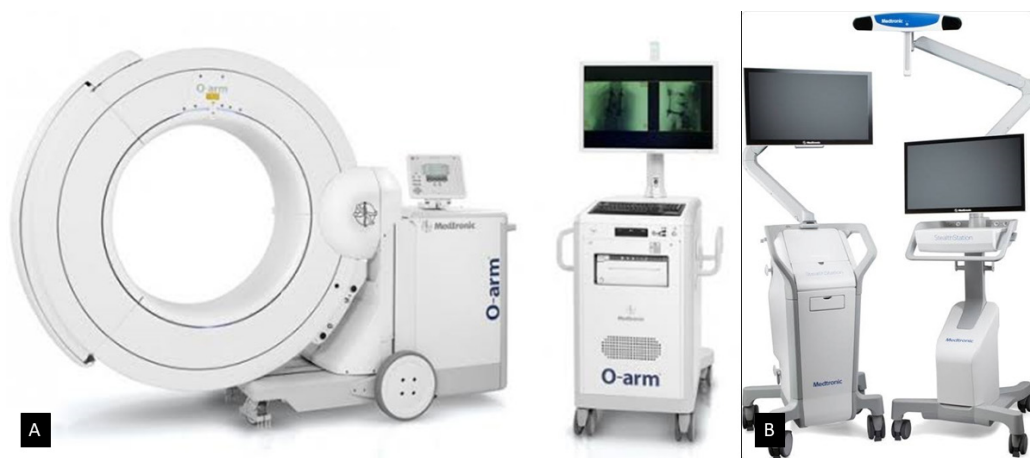on computed tomography (fan beam or cone beam), and total three-dimensional navigation.

## 2.2. Single or biplanar fluoroscopy (non-navigated)

The MIS procedures started with the use of C-Arm fluoroscopy. It is cumbersome as the position of the C-Arm needs to be continuously changed for anteroposterior and lateral views, thus, considerably increasing the operating time. It has been superseded by the O-arm fluoroscopy, which allows both AP and lateral views simultaneously (Figure 1A). In both cases, the instrumentation is done with a free-hand technique under continuous imaging. These are cheap and can be used in other surgical procedures, thus still in use at many centers. However, it has major limitations. The most significant drawback is the radiation exposure both for the operating team and for the patient. It requires a K-wire over which the rest of cannulated instruments are passed. So, the k-wire-associated complications are possible. The image quality is affected by obesity and, the reported accuracy of this method was lower. As an advancement, navigation technology was added to these existing imaging facilities.

## 2.2. Navigated two-dimensional fluoroscopy

The C-arm and O-arm fluoroscopy provide two-dimensional images. The introduction of navigation technology provided better accuracy in screw placement and reduction of radiation exposure (Figure 1B).



**Figure 1** | (A) O-Arm intraoperative three-dimensional (3D) imaging system. (B) Stealth station S8 navigation system.

It requires the installation of a reference frame to a fixed point like the iliac crest or a spinous process. It must not be moved once the image has been acquired. The rest of the instruments are then registered and projected onto a fluoroscopy monitor to correspond 2-dimensionally with the imaging anatomy. Despite being advantageous over existing techniques, this method is still limited due to image quality due to the use of the same imaging technology. Also, the navigation process is virtual and subject to errors.

### **2.3. Fan beam and cone beam computed tomography-based three-dimensional navigation**

With the advancement in imaging technology and computational abilities, it is possible to render real-time three-dimensional imaging with an intraoperative acquired image. An intraoperative CT scanner or a C-arm/O-arm is used for imaging. The images on the screen are projected as 3D reconstruction. It improves the accuracy, while no K-wire guidance is required. It still requires a reference array with subsequent calibration of all the instruments. There is no radiation exposure for the operating team as they remain outside while the image is acquired. The patient is also exposed only twice. Firstly, at the beginning of the procedure and secondly at the end for confirmation of correct implant insertion.

The commonly used systems of this category of technology include Airo (Mobius imaging, Shirley, MA, USA) with navigation software (Brainlab, Munich, Germany) (fan beam based intraoperative CT system), O-arm with stealth station (Medtronic, Minneapolis, MN, USA), and the C-arm based Ziehm Vision FD Vario 3-D with open navigation software integration capabilities (Ziehm Imaging, Orlando, FL, USA). The cost is a major deterrent in the acquisition of these technologies. However, some studies have proved them to be cost-effective by reducing the overall operating time as compared to previous techniques.

### **2.4. 3D “total navigation”**

This technology aims to eliminate the usage of fluoroscopy. Even in cases done with 3D navigation, fluoroscopy is needed to select proper interbody cage implants to be inserted by lateral or transforaminal approach. With this technology, the cage measurements can be done before insertion on the 3D reconstruction images provided



by the software, and later inserted under navigation guidance. Subsequently, it allows insertion of the pedicle screws also thus patient re-positioning is not required. It has been employed in performing MIS-TLIF and percutaneous cervical interfacet joint cages.

### **3. Advances in optics and visualization technology**

Endoscopic spine surgery is now heading toward full endoscopic procedures with uni-portal or bi-portal techniques.(5) Advances in optics and display technology have allowed better visualization of anatomical structures. Improved appreciation of even small anatomical landmarks significantly helped in working in limited spaces.

Rigid rod lens endoscope systems are currently being used in most MIS-spine cases. The Yeung Endoscopic Spine System (YESS) and the Thomas Hoogland Endoscopic Spine System (THESSYS) have been landmarks in the history of advancement in endoscopic technology. The improved optics and illumination system is backed by the advanced display system. Currently, the organic light emitting diode (OLED) screens represent the most advanced technology providing ultra-high-definition (UHD) images. Despite multiple advantages and its continuous improvement, the limited life span of OLED is a concern.

### **4. Instruments and implants**

The progressively narrowed corridor of access in MIS needs specially designed instruments to reach the target site, implants that can be negotiated through it, and powered tools like drills and energy sources to perform tasks rapidly and with ease. Accordingly, there have been multiple innovations in this segment.(6)

#### **4.1. Drill**

Maneuvering drill burr in all directions is difficult during ESS. It may also result in inadvertent injury to the scope tip. Thus, a new innovative design involved burr heads that could move in all directions. There has been progressive improvement in the designs. Currently, the tip-controlled bur designed by Chongqing Xishan Science & Technology Co., Ltd. (China) offers a drill with a burr that can move

on both the x and y-axes. The whole endoscopic access corridor need not be manipulated while performing adequate bony resection, even at the edges.

## **4.2. Expandable cages**

Performing interbody fusion with uniportal endoscopy is a challenge. It has been made possible by the introduction of expandable cages. They are classified based on the direction of their expansion. They initially come collapsed. Once they are inserted inside the disc space, they are expanded vertically to maintain disc height, and horizontally to provide a greater footprint for stability. Thus, through limited access amounting to a small keyhole, interbody cages can be introduced to improve fusion rate, sagittal balance, indirect decompression, and overall outcome.

## **4.3. Energy sources**

Energy sources allow surgeons to perform more rapid and precise resection, more so with limited access like in MISS. There has been a continuous use of lasers and electrical and radiofrequency ablation technology in herniated discs. With the advent of MIS for intradural pathologies, more advanced energy sources are required to maintain hemostasis and perform rapid decompression of tumors. There has been tremendous advancement in energy sources that are currently used in other sub-specialty minimally invasive surgery. Vapor pulse coagulation (VPC), smart electrode technology, ultrasonic energy, Ligasure system, and harmonic scalpel technologies are only a few examples of energy sources that can be applied in MISS with little modifications.

## **4.4. Expansion of MISS applications with advanced technology**

With an expanded armamentarium of advanced technology at the MIS surgeon's disposal, the applications of MISS have also increased. Due to cutting-edge navigation technology, it has become possible to perform thoracic and even cervical surgery as they require greater precision as compared to the lumbosacral region. Minimally invasive cervical pedicle screw fixation (MICEPS) via post-erolateral approach and minimally invasive C1-C2 posterior fixation via

post-erolateral approach has already been described with the use of 3D navigation technology. MI-TLIF and OLIF (oblique lumbar interbody fusion) procedures have been made more accurate, with lesser operative time and radiation exposure with the newer navigation technologies. MIS fusion and reconstruction in complex spine diseases and deformity is now being performed with CT (O-arm) based, virtual reality-based, or augmented reality-based navigation. To achieve correct sagittal balance and lordosis improvement, mini-open techniques are still used along with minimally invasive techniques. Present technology needs further improvement to correct the complex deformities with MIS alone.

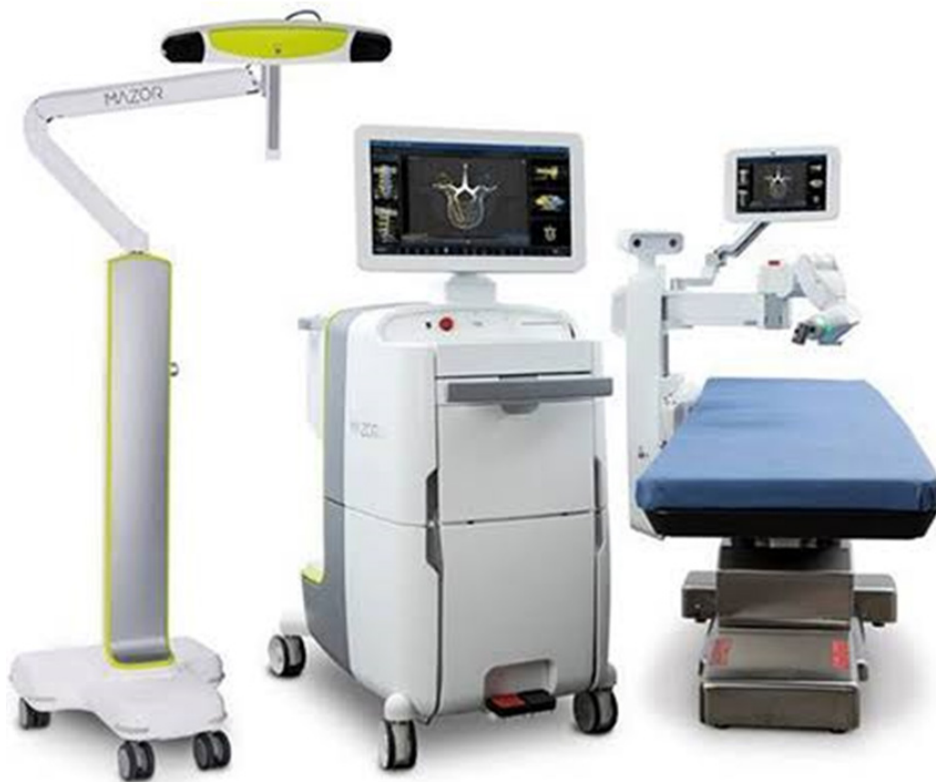State-of-art endoscopes and drills have expanded the indication of MISS to include intradural tumors also. With the induction of advanced energy sources and navigation technologies, it is expected that larger tumors could be easily resected with a limited corridor. The application has extended to treat vascular malformation of the spine with minimal access. With the advent of expandable cages, interbody fusion can be performed endoscopically through the trans-foraminal or oblique corridor. Most disc herniation can be treated with uniportal or biportal endoscopic systems with no need for general anesthesia and as a daycare procedure.

#### **4.5. Future perspective**

The last two decades have seen tremendous growth in the field of MISS. Most of them have been applications of technology from the field of space technology and the entertainment industry. While few disruptive innovations like the YESS and THESSYS in MISS have been a major boost to the technique and technology.<sup>(3)</sup> Each technological advancement acts as a building brick for another. The existing technology in MISS has formed the foundation for the incursion of high-end technologies like robotics, nano-technology, virtual reality, artificial intelligence, and photonics.

### **5. Robotics and artificial intelligence**

The improved navigation systems have high accuracy and precision, which has been utilized in performing implant and screw insertion with robotic arms (Figure 2). With the 3D navigation system, the insertion point, trajectory, and final point of screw insertion are



**Figure 2** | Mazor X spine robotic system.

pre-determined. The robotic arm once fed with the data can then perform the procedure with a greater degree of accuracy than the existing techniques. The next step of advancement in this technology is where image acquisition, initial planning, and execution could be performed solely by robotics. Recent advances in artificial intelligence (AI) technology have allowed the conception of such possibilities.(4) Improved machine learning, neural networking, robotics, expert systems, fuzzy logic, and natural language processing, the six major subsets of AI, have already brought significant changes in other aspects of the medical specialty.

### **5.1. Augmented and virtual reality**

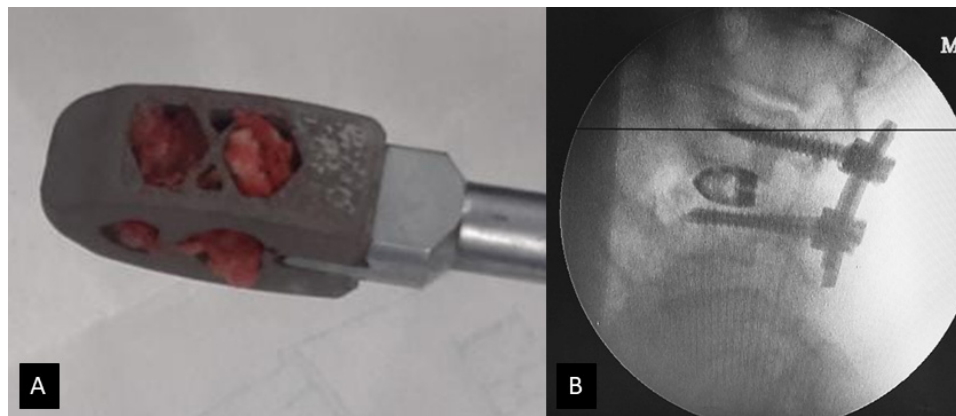
The augmented reality system involves the projection of preoperatively identified anatomical structures, tumors, implant space, or screw trajectory/final position as a superimposed image on the anatomy visualized in the operating room through the microscope, display, or special goggles. This allows targeted exposure to the area of interest in case of tumors. Also, it ensures visualization of all

the margins of the tumor to confirm complete resection. Real-time guidance is provided during screw and intervertebral cage insertion, including correct alignment of the corridor systems.

Virtual reality systems have been mostly used for teaching purposes and preoperative planning, which involves simulation of real-world situations, allowing acquaintance with the pathological anatomy and surgical goals during MISS.

## 5.2. Nanotechnology and photonics

Nanoparticles, by their size, possess unique physical, chemical, and biological properties. They have already been inducted into the MIS armamentarium. Nano-roughened titanium cages offer greater fusion rates (Figure 3). Nanoparticles with polyvinyl alcohol polyvinyl pyrrolidone composite have been reported as an excellent replacement for the intervertebral disc. They have been used in neural regeneration, CNS drug delivery, molecular imaging, and the management of osteoporosis.



**Figure 3 | (A)** An interbody cage with the surface modified to enable a blend of surfaces at the macro, micro, and nano levels on every surface of the implant. It uses “biomimicry” of the osteoclastic pit geometry to mimic structures involved in the bone remodeling process. **(B)** Intraoperative C-Arm lateral view of the lumbar spine following MI-TLIF (using nanotechnology-based interbody cage) and percutaneous pedicle screw insertion.

Photonics is the physical science of light waves. Endoscopes, light sources, and display technology form a major part of the gamut of MIS. The photonics revolution has made it possible to have the present-age devices, systems, and integrated circuits for application in high-speed data communication, advanced sensing,

and imaging. Thus, it can improve all the aspects of present and future MIS technologies.

### 5.3. Conclusion

There has been rapid advancement in MIS technology, making it more precise and accurate. The spectrum of applications has been expanding. Cutting-edge technologies involving optics, instruments, and navigation have allowed MIS to supersede the existing techniques of spine surgery. Still, there is a huge scope for further advancement due to the ongoing revolution in AI, robotics, and other basic sciences.

### References

1. Moon A, Rajaram Manoharan S. Endoscopic spine surgery: current state of art and the future perspective. *Asian Spine J.* (2018) 12:1–2.
2. Hussain I, Cosar M, Kimaz S, Schmidt F, Wipplinger C, Wong T, et al. Evolving navigation, robotics, and augmented reality in minimally invasive spine surgery. *Glob Spine J.* (2020) 10:22S–33S.
3. Akbary K, Kim J. Recent technical advancements of endoscopic spine surgery with disparate or disruptive technologies and patents. *World Neurosurg.* (2021) 145:693–701.
4. Kim J, Härtl R, Wang M, Elmi-Terander A editors. *Technical Advances in Minimally Invasive Spine Surgery: Navigation, Robotics, Endoscopy, Augmented and Virtual Reality*. Singapore: Springer Nature Singapore (2022). doi: 10.1007/978-981-19-0175-1
5. Tieber F, Lewandrowski K. Technology advancements in spinal endoscopy for staged management of painful spine conditions. *J Spine Surg.* (2020) 6:S19–28.
6. Snyder L, O'Toole J, Eichholz K, Perez-Cruet M, Fessler R. The technological development of minimally invasive spine surgery. *BioMed Res Int.* (2014) 2014:1–9.